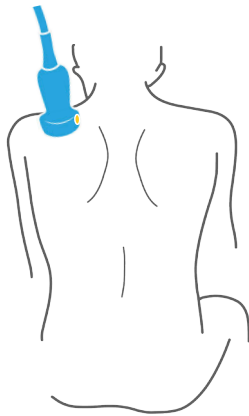


Mastering upper extremity nerve blocks

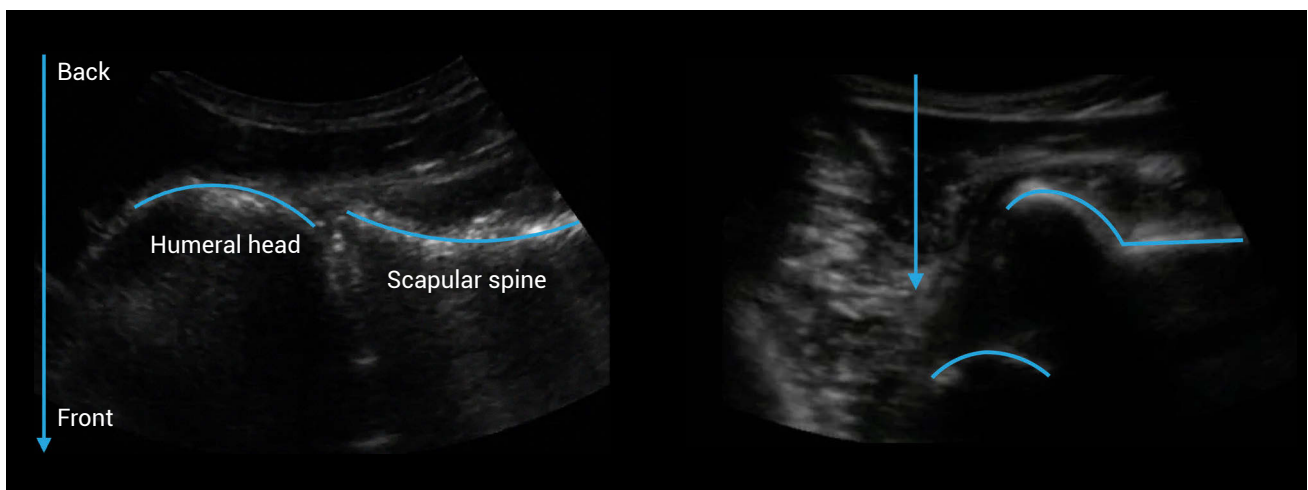
IMAGING A SHOULDER DISLOCATION

Probe position



Shoulder dislocations can be difficult to manage. They can be time and resource consuming. Occasionally, there is some diagnostic uncertainty (i.e., Is the shoulder dislocated or is the humerus fractured?). Bedside ultrasound can confirm a dislocation in a matter of seconds. This lesson describes how.

Once a dislocation is confirmed, you can then inject the joint with local anesthetic using ultrasound guidance. This can help you avoid a time and resource consuming procedure.



Normal anatomy of the shoulder

Anterior shoulder dislocation
(Note: the humeral head is displaced away from the probe.)