

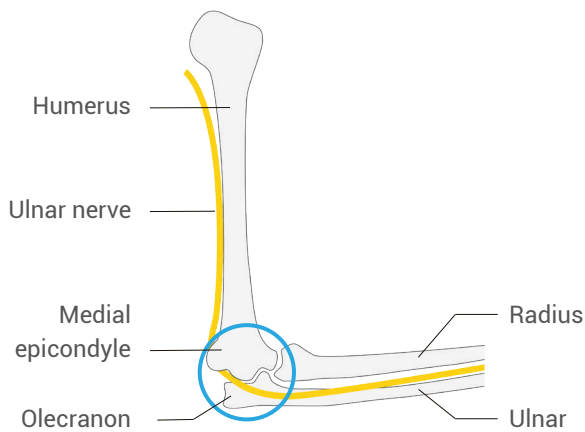
Mastering upper extremity nerve blocks

UNCOVERING THE NERVES OF THE UPPER EXTREMITY

The arm offers a series of nerves that are highly accessible using ultrasound guidance. Given the amount of both simple and complex injuries to our hands and arms, learning how to reliably block these nerves will provide you with cleaner, safer, and faster treatment options. This chapter will give you easy anatomic guides to quickly find each nerve with ultrasound.

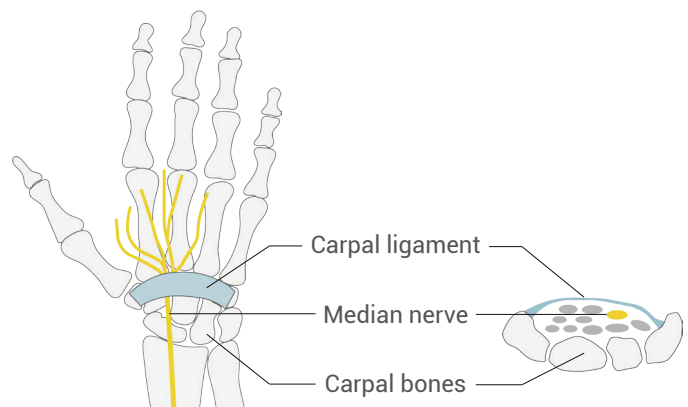
Ulnar nerve

Start in the cubital tunnel



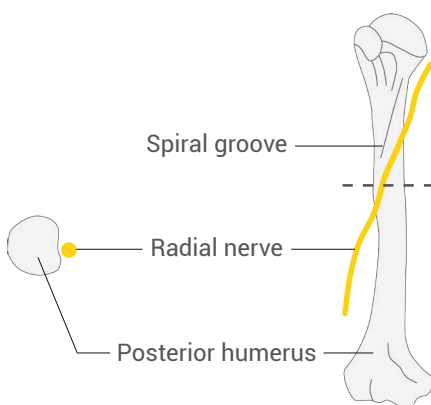
Median nerve

Start in the carpal tunnel



Radial nerve

Spiral groove of the humerus



This chapter also provides a bonus lesson on identifying shoulder dislocations and how to use ultrasound to inject the shoulder, to help reduce the need for any intravenous narcotics or sedatives.