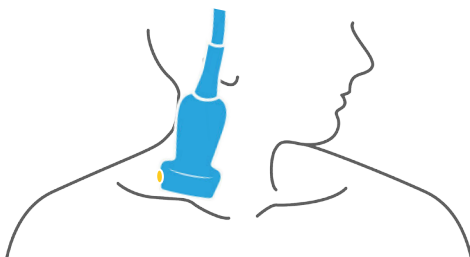

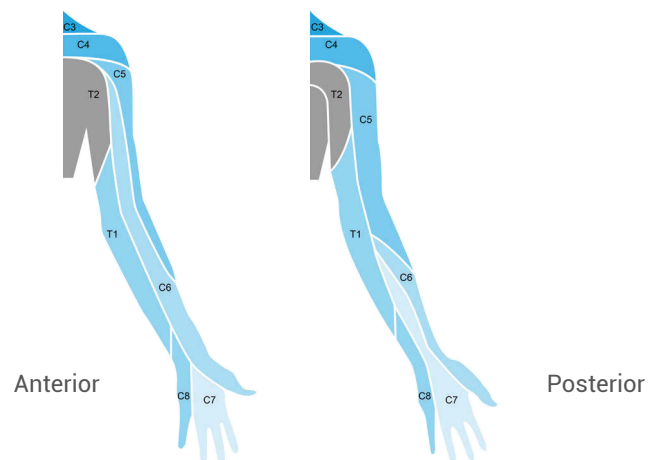
## Pain in the neck

# PERFORMING AN ULTRASOUND- GUIDED SUPRACLAVICULAR BRACHIAL PLEXUS BLOCK

### Probe position



### Distribution



### Tips for success

- Use a linear ultrasound probe.
- Landmarks:
  - Find the subclavian artery.
  - Direct your eyes just lateral and superficial to it where you will see the brachial plexus, a group of hyperechoic nerve roots.
- \*Unlike other nerves in the body, the nerve roots above the clavicle appear darker and more hypoechoic (notice this when you see the nerves in the arms and legs which are much more hyperechoic).
- Place color Doppler on this target area to ensure there are no vessels in your expected needle path.
- Locate the pleural line and lung sliding.
- Note the depth of this pleural line and ensure you use a needle that is unlikely to reach this pleural line. This will help you avoid a pneumothorax.
- Do the procedure in-plane.
- Use 10–15 mL of anesthetic.

### Indications

- Will anesthetize nerve roots C5–T1:
  - arm procedures (laceration repairs, abscess drainage)
  - shoulder dislocations
  - elbow dislocations
- Occasionally, this block will miss C8–T1 (ulnar distribution).
- Expect it to affect the ipsilateral phrenic nerve and cause temporary hemidiaphragm paralysis.
  - \*Thus, do not perform in patients with baseline lung dysfunction.