ORBITAL

Evaluating for critical ocular pathology

Retinal detachment

Retinal detachment is seen best with reduced gain. It appears as a ribbon-like structure, attached to the posterior wall, within the vitreous chamber.

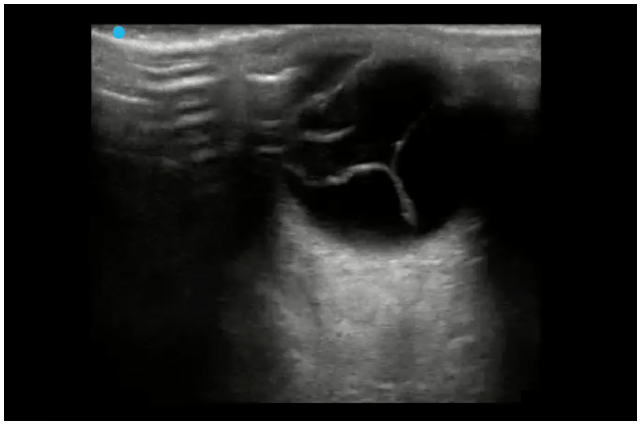

Vitreous hemorrhage

Vitreous hemorrhage is seen best with increased gain and during a kinetic exam (moving eye). It appears as detached hyperechoic particles floating within the vitreous chamber.

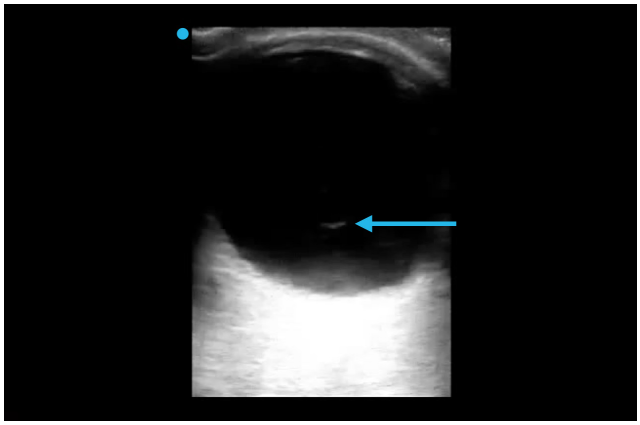

Posterior vitreous hemorrhage

A posterior vitreous hemorrhage has a hyperechoic free-floating seaweed-like appearance, best seen with increased gain and during a kinetic exam.

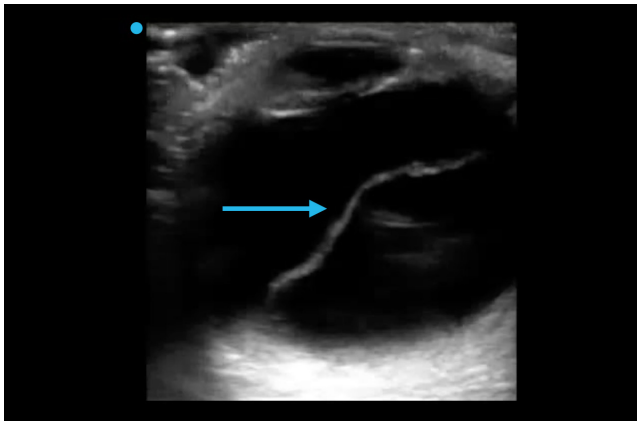

Globe rupture

A globe rupture of the orbit is the loss of the normal round shape. If this is noted, remove the probe and do not put any further pressure on eye.

Foreign body

A foreign body appears as hyperechoic material with a shadow (often in the form of a ring-down artifact) within the orbit.

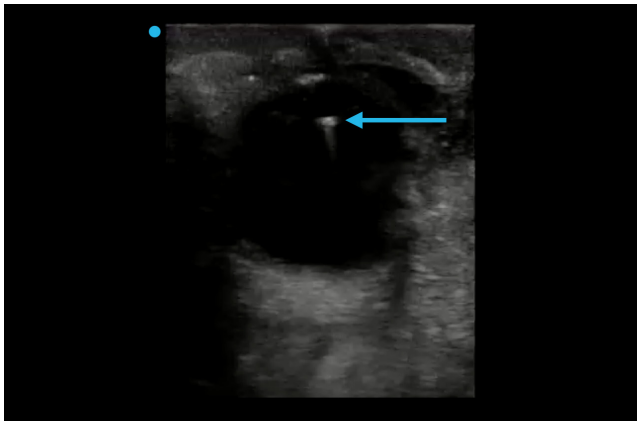

Lens dislocation

Lens dislocation is indicated with the presence of a hyperehoic lens within the vitreous chamber.

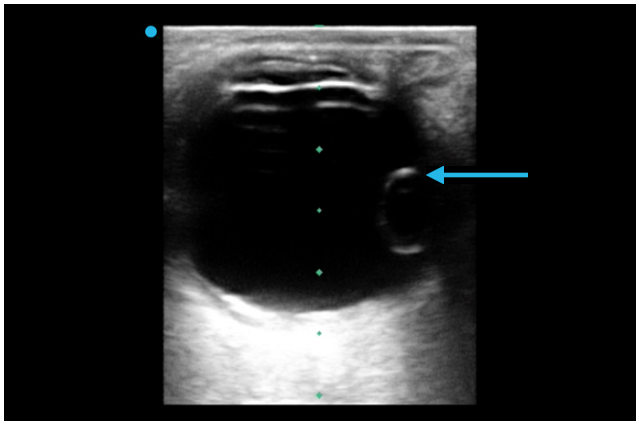

Retrobulbar hematoma

Retrobulbar hematoma appears as anechoic fluid posterior to the orbit, in a traumatic patient.