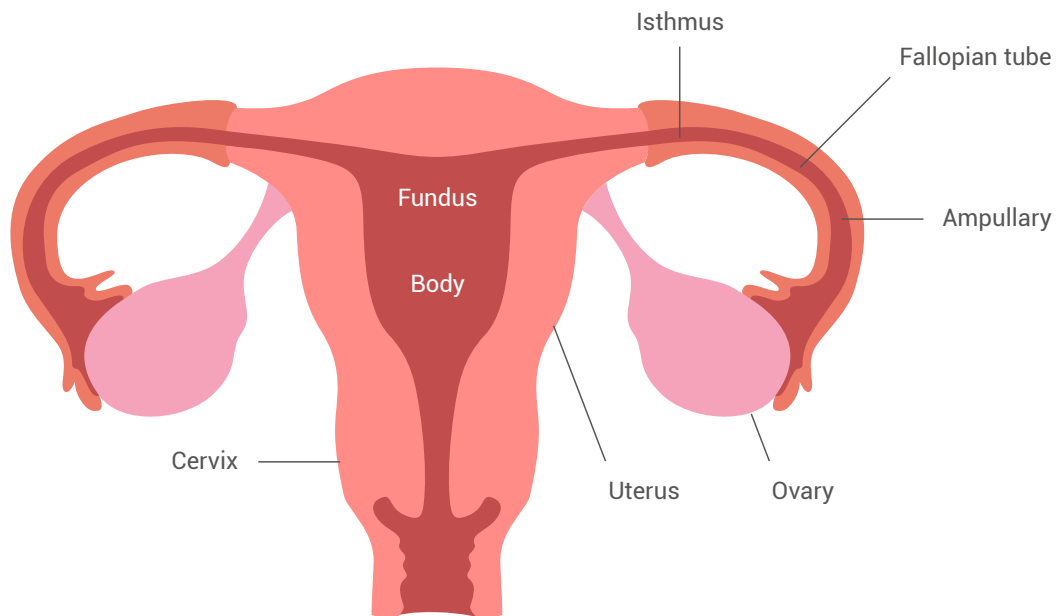


# FIRST TRIMESTER PREGNANCY

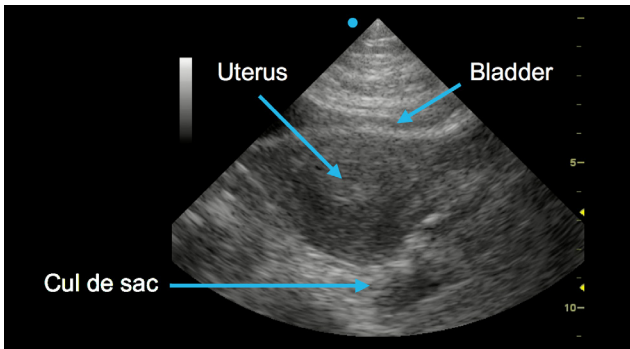
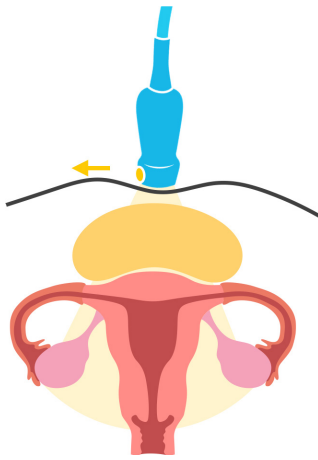
## Performing a pelvic ultrasound study



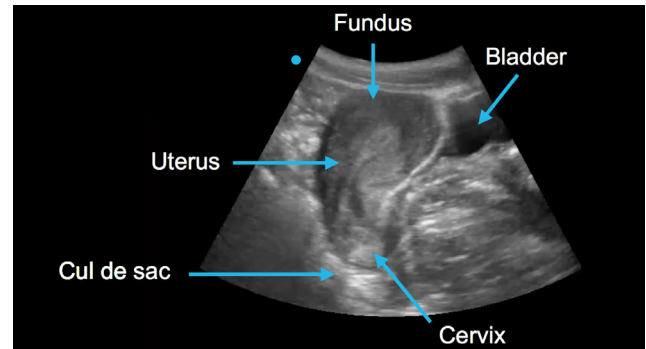
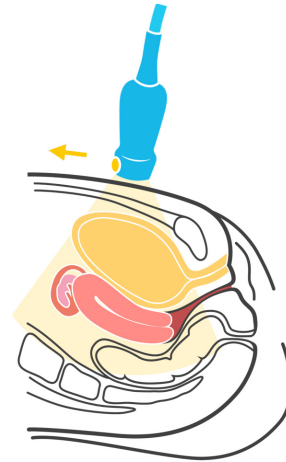
For a pelvic ultrasound study you would use a transabdominal or endocavitary probe depending on gestational age.

<b>Gestation</b>	Later (> 8 weeks)	Earlier
<b>Bladder</b>	Full	Empty
<b>Scanning field</b>	Wide	Narrow
<b>Resolution</b>	Less	Increased

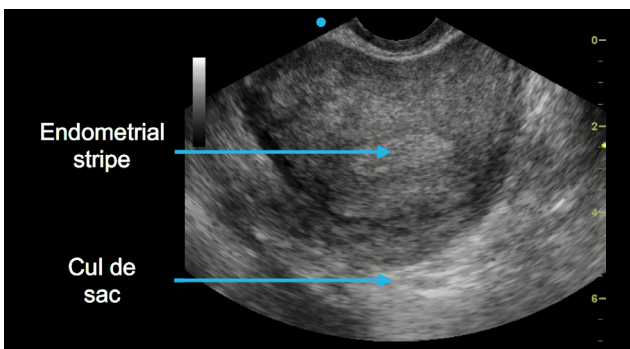
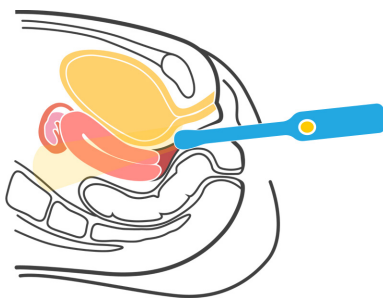
### Transabdominal short-axis view



### Transabdominal long-axis view



### Endocavitary short-axis view



### Endocavitary long-axis view

