

LUNG ULTRASOUND

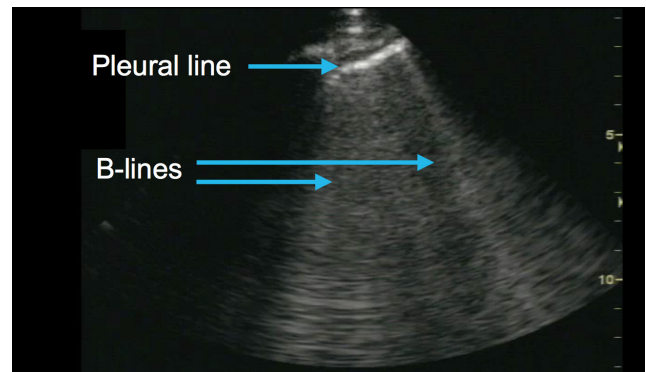
Identifying B-lines and pleural effusions

B-lines

B-lines are an indication of fluid in the lung. They look like large bright lung “rockets” or “search lights” coming off the pleural line, extending down to a depth of at least 16 cm.

Two or more B-lines per zone (1–3) is considered a positive lung field for fluid.

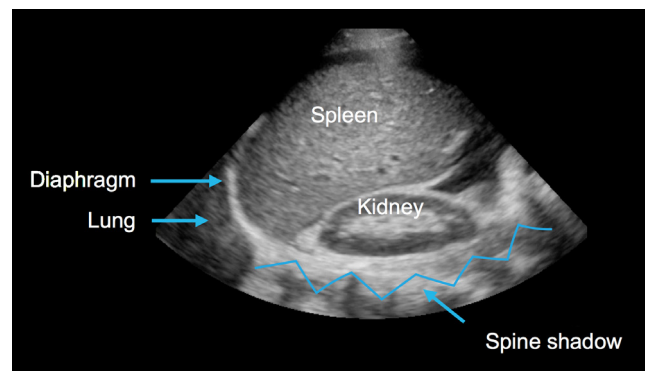
Two or more positive lung fields bilaterally is indicative of pulmonary edema.



Pleural effusions

In a normal ultrasound image of zone 4, the spine shadow cannot be seen beyond the diaphragm.

While you are looking for B-lines in zones 1–3 (to identify fluid in the lung), in zone 4 you will look for the spine sign as an indication of a pleural effusion.



Spine sign

The spine sign is the visualization of the spine shadow beyond the diaphragm in the lung zone 4 (RUQ or LUQ) and signifies the presence of a pleural effusion.

