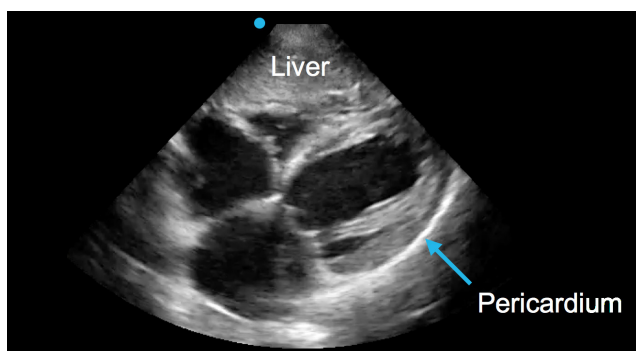
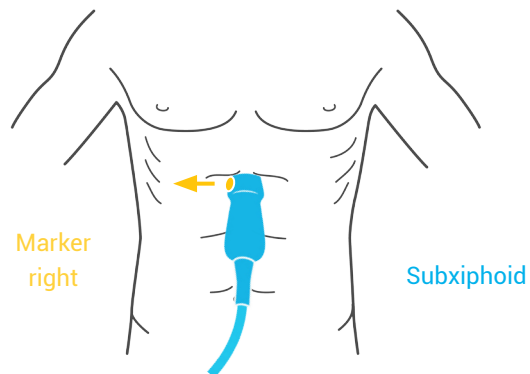


EFAST

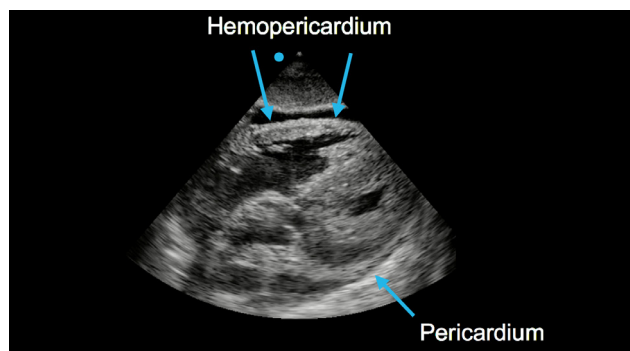
Obtaining the subxiphoid view

The subxiphoid view is useful to look for a traumatic pericardial effusion.

Using the phased-array probe, place the probe under the xiphoid process with the indicator towards the patient's right side, and aim up into the chest. You should be able to visualize the entire heart, and surrounding pericardium.



Normal



Abnormal (positive)