

# ECHO MASTERCLASS— ADULT CONGENITAL HEART DISEASE



Cathy West

# Table of contents

## Getting the basics right

Image orientation	05–08
Cardiac morphology and anatomy	09–18

## Simple shunts

Simple shunts	22–23
Hemodynamics	24–27
Atrial septal defects	28–35
Ventricular septal defects	36–38
Patent ductus arteriosus	39–41

## Atrioventricular septal defects

Atrioventricular septal defects	45–46
Partial atrioventricular septal defect	47
Complete atrioventricular septal defect	48–49

## Left ventricular outflow lesions

Left ventricular outflow lesions	53
Dynamic left ventricular outflow tract obstruction	54
Fixed left ventricular outflow tract obstruction	55–56
Valvular aortic stenosis	57–62
Supravalvular aortic stenosis	63
Coarctation of the aorta	64–66

## **Coronary artery disease**

Coronary disease	70
Congenital anomalies	71–72
Anomalous left coronary artery from the pulmonary artery	73–75
Kawasaki disease	76–77

## **Ebstein anomaly**

Ebstein anomaly	81–82
-----------------	-------

## **Right ventricular outflow lesions**

Right ventricular outflow lesions	86–92
-----------------------------------	-------

## **Tetralogy of Fallot**

Tetralogy of Fallot	96
Tetralogy of Fallot in babies	97–99
Repair of Tetralogy of Fallot	100–101
Postoperative assessment in adults	102–105

## **Transposition of the great arteries**

Transposition of the great arteries	109–110
Simple transposition	111–121
Congenitally corrected transposition of the great arteries	122–124

## Chapter 1

# GETTING THE BASICS RIGHT

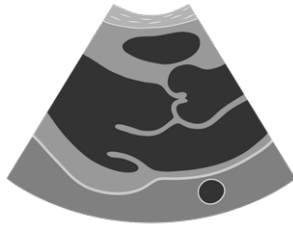


# Image orientation

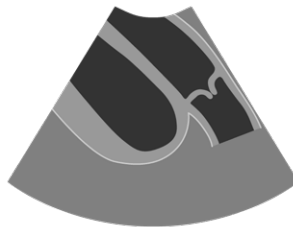
Let's cover the basic concepts of image orientation utilizing the standard views used in adult echo.

## Parasternal long-axis view (PLAX)

Normal or main PLAX view



Right ventricular outflow view



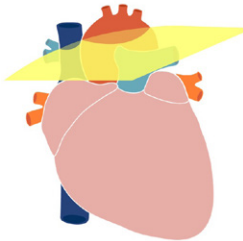
## Parasternal short-axis view (PSAX)

### Mitral valve level



### Aortic valve level

- To get from the mitral valve view to the aortic valve, we pan superiorly.



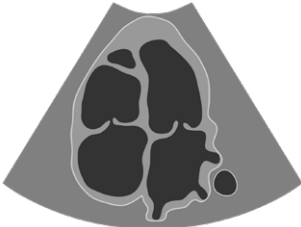### Papillary muscle level

- To get from the mitral valve level to the papillary muscles, we pan inferiorly.

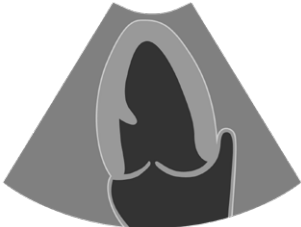

# Apical views

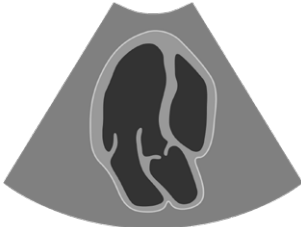## Apical four-chamber view



## Apical two-chamber view

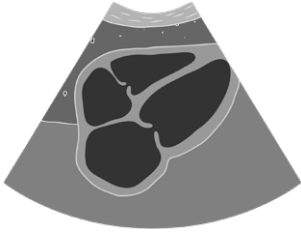


## Apical long-axis view (also called three-chamber view)



## Subcostal views

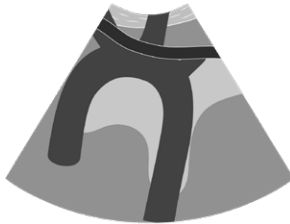
**Subcostal four-chamber view**



**Situs view**



**Suprasternal view**



Understanding image orientation is important in congenital imaging because it is frequently necessary to describe the spatial relationship of defects or vessels with reference to each other.

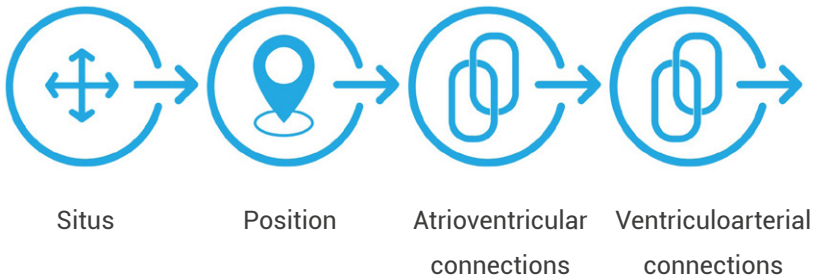- Establishing situs—is the inferior vena cava to the left or the right of the spine?
- Position of a secundum atrial septal defect—within the atrial septum, is it anterior (close to the aorta) or posterior (closer to the coronary sinus)?
- Transposition of the great arteries—the aorta is usually anterior but is it to the left or right of the pulmonary artery?



# Cardiac morphology and anatomy

In many cases, echocardiography is requested to assess heart function. In congenital imaging, before function can be assessed, the cardiac connections must be assessed to determine the anatomy of the heart. Normal connections are often assumed in adult cardiology but in pediatric and congenital echocardiography, normal connections have to be proven.

This requires a strategy, which uses building blocks to bring the connections together and arrive at a final diagnosis for the cardiac anatomy. This strategy is called the sequential segmental analysis.



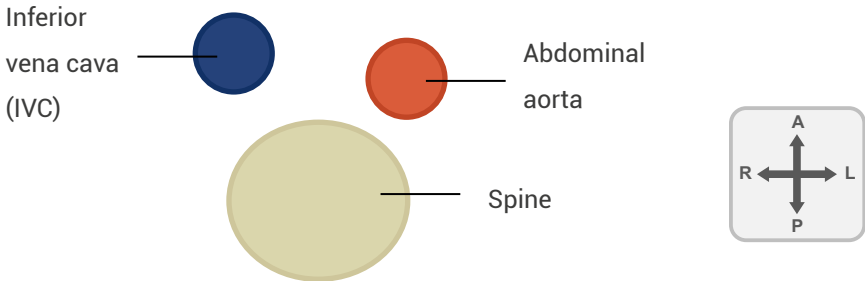
## The sequential segmental analysis focuses on four areas

1. Cardiac situs—based on the relationship of the inferior vena cava and aorta with the spine.
2. Cardiac position—based on the direction of the apex of the heart.
3. Atrioventricular connection—based on the relationship between the atria and the ventricles.
4. Ventriculoarterial connection—based on the relationship between the ventricles and the great arteries.

# Step 1 –determining cardiac situs

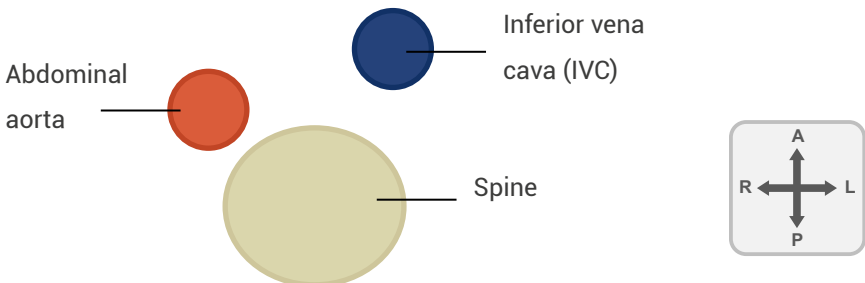
*There are four main arrangements*

## Situs solitus = normal



- The inferior vena cava is to the right of the spine, the aorta is to the left of the spine.
- This represents the normal atrial arrangement and indicates the left atrium is on the left side of the heart.

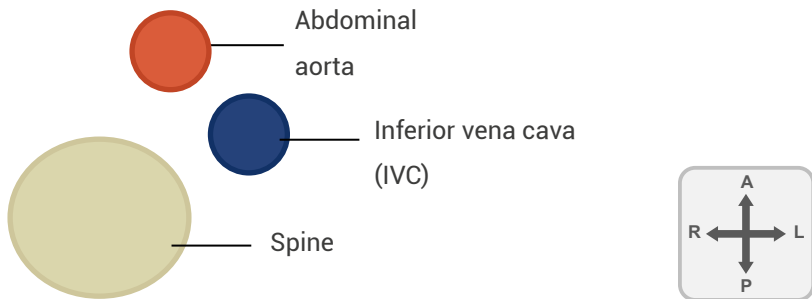
## Situs inversus = mirror image



- The inferior vena cava is to the left of the spine, the aorta is to the right of the spine.

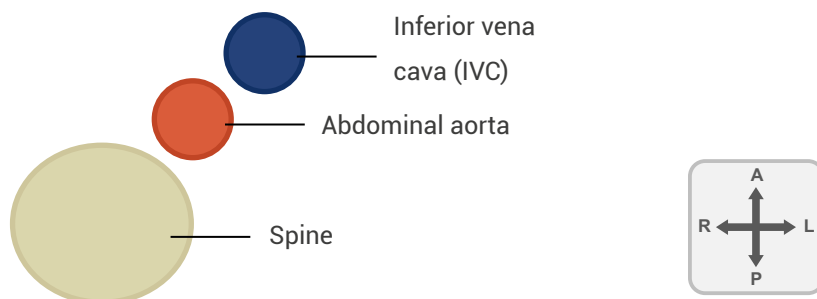
- This is the inverse of the normal arrangement.
- There is still one left and one right atria but the atrium which has morphological features of a left atrium (such as the long, finger-like appendage, smooth walls, and pulmonary veins) is located on the right side of the heart.
- The right atrium (with systemic veins, pectinate muscles, a coronary sinus, sinoatrial node, and a eustachian valve) will be located on the left side of the heart.

### Left isomerism = polysplenia



- Both the inferior vena cava and aorta are on the same side of the spine, with the aorta the most anterior.
- In this case both atria are morphologically formed as left atria. They both have long, finger-like appendages and smooth walls.
- Pulmonary veins can enter one or both atria. The inferior vena cava is interrupted and venous blood from the lower body drains via the azygous vein, to the superior vena cava. The hepatic veins drain directly into the right-sided atrium.

## Right isomerism = asplenia



- Both the inferior vena cava and aorta are on the same side of the spine, with the IVC the most anterior.
- In right atrial isomerism both atria are morphologically formed as right atria. Bilateral superior vena cava are common. Total anomalous pulmonary venous return is also common.
- Right isomerism is frequently associated with complex congenital heart disease such as atrioventricular septal defect, double outlet right ventricle or transposition of the great arteries.

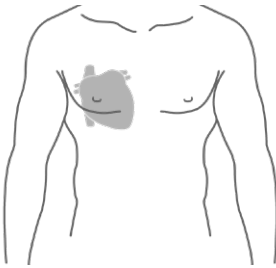
Both left and right isomerism are part of a wider complex called heterotaxy syndrome. This involves extracardiac anomalies including the viscera and the lungs.

## Step 2—determining cardiac position

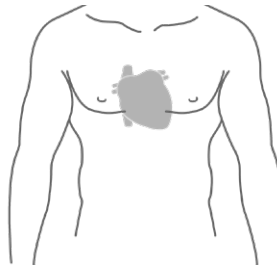
Determining cardiac position is a two-step process. One is to identify the location of the heart within the chest cavity—this is cardiac position.

**Cardiac position describes where in the chest the heart is located**

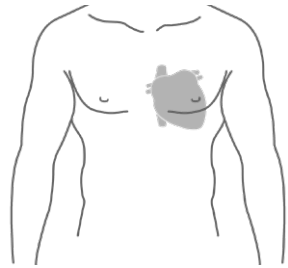
- Dextroposition—on the right
- Mesoposition—midline
- Levoposition—on the left (normal)



Dextroposition



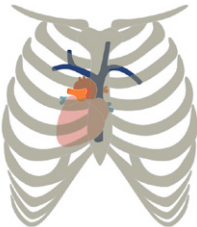
Mesoposition



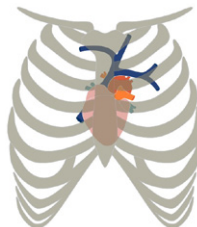Levoposition

**There is another factor to consider—direction of the cardiac apex**

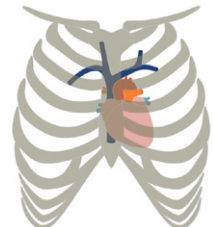
- Dextrocardia—apex pointing to right chest
- Mesocardia—apex pointing straight down toward feet
- Levocardia—apex pointing to left chest (normal)



Dextrocardia

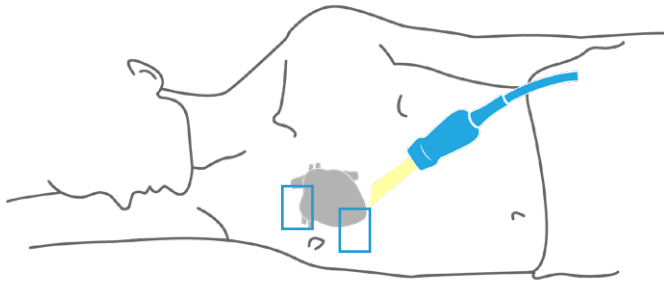


Mesocardia



Levocardia

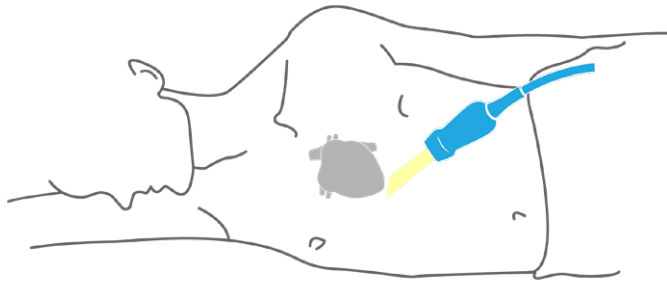
The normal location for the heart is levoposition with levocardia. Where position and direction of the apex are the same, the term position is dropped; the normal heart is usually just described as levocardia. It is possible though to have variance (e.g., dextroposition with levocardia), the heart on the right side of the chest but apex pointing toward the left chest.



*When scanning a patient with dextrocardia, roll the patient into the right lateral decubitus position and scan from the right parasternal and right apical views.*



*Keep the transducer in the same position to avoid confusion between left and right image orientation (i.e., in the apical four-chamber view, keep the index marker at three o'clock, so left is still displayed in the usual position on the screen). This is important to maintain standardization in image acquisition and to avoid confusion for anyone viewing the images who cannot know if the transducer position was altered.*



*When scanning a patient with mesocardia, it's possible that the only reliable window is the subcostal view because the apex is often behind the sternum. Try both left and right lateral decubitus positions—the acoustic windows in these patients are widely variable.*

### Step 3—determining atrioventricular (AV) connections

Atrioventricular connections describe the relationship between the atria and the ventricles but also incorporate the AV valve. The AV valve should be considered as part of the ventricle.

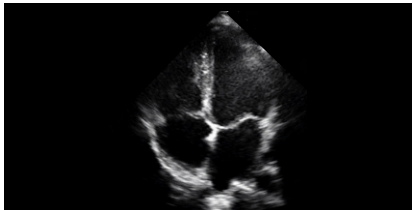
In a normal heart, where the left atrium connects to left ventricle, there is AV concordance.

Focusing on the cardiac crux is an important element to determining the AV connection. In the normal heart, the tricuspid valve is displaced towards the apex, which causes the normal offset of the AV valves.

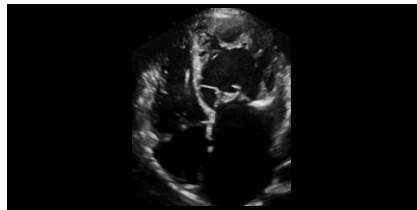In complex congenital heart disease, the most reliable method of identifying the ventricles is to confirm the location of the right ventricle. This is because it has several unique features, which can be identified using echocardiography.

- Tricuspid valve offset
- Moderator band
- Tricuspid valve insertion directly into the ventricular septum
- Usually the most anterior ventricle

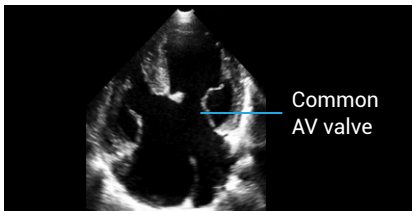
Below are some commonly seen variations of AV concordance



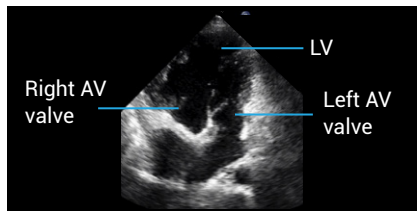
Normal AV concordance



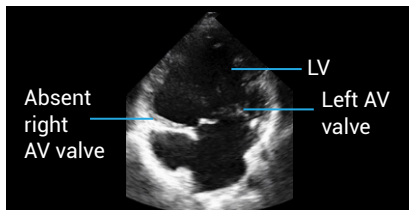
AV discordance



Complete AVSD



Double-inlet LV



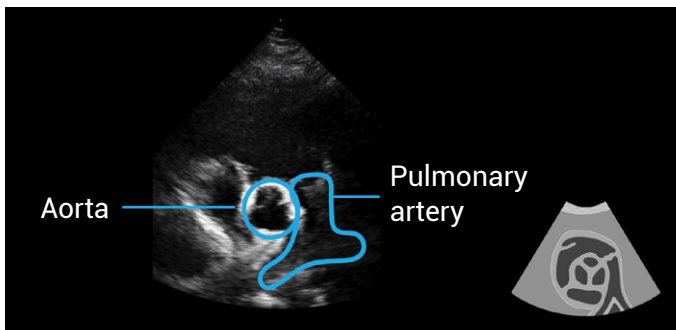
Tricuspid atresia



## Step 4—determining ventriculoarterial connections

Ventriculoarterial connections describe the relationship between the ventricles and the great arteries. It also includes identifying that two arteries exist and determining if they are functional.

In the normal heart, the aorta comes from the left ventricle and the pulmonary artery comes from the right ventricle—this is ventriculoarterial (VA) concordance. They also have a special crossover relationship, which is nicely illustrated in the short-axis views where the aorta is seen in transverse and the pulmonary artery in the longitudinal

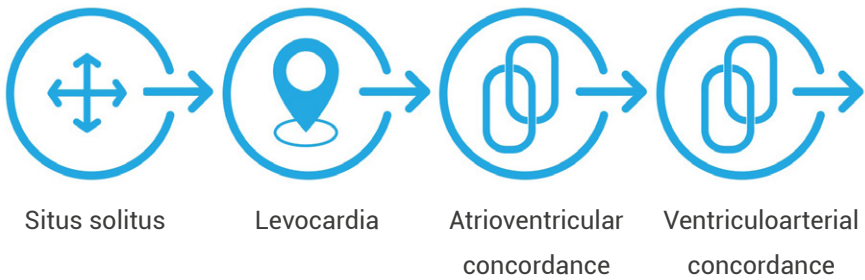


The origin of the aorta and the pulmonary artery look very similar on echo, so we need to prove which is which. We cannot reliably identify them using position or ventricular connection, however, there are two identifying features.

1. The pulmonary artery bifurcates—follow the main pulmonary artery until a bifurcation is seen, rather than an aortic arch.
2. The coronary arteries arise from the aorta.

Once the sequential segmental analysis has been completed, the assessment of heart function and for intracardiac lesions such as valvular or septal defects can begin.

A normal heart is described as situs solitus, levocardia, atrioventricular and ventriculoarterial concordance.



## Further reading

Alonso-González, R, Dimopoulos, K, Oliver, JM, et al. 2010. The right heart and pulmonary circulation (IX). The right heart in adults with congenital heart disease. *Rev Esp Cardiol.* **63**: 1070–1086.

[PMID: 20804703](#)

Baumgartner, H, Bonhoeffer, P, De Groot, NM, et al. 2010. ESC Guidelines for the management of grown-up congenital heart disease (new version 2010). *European Heart Journal.* **23**: 2915–2957.

[PMID: 20801927](#)

Di Salvo, G, Miller, O, Babu Narayan, S, et al. 2018. Imaging the adult with congenital heart disease: a multimodality imaging approach-position paper from the EACVI. *Eur Heart J Cardiovasc Imaging.* **19**: 1077–1098.

[PMID: 30084968](#)

Eidem, BW, Cetta, F, and O'Leary PW. 2010. *Echocardiography in pediatric and adult congenital heart disease*. 2nd edition. Philadelphia: Lippincott Williams & Wilkins.

Gatzoulis, M, Webb, G, and Daubeney, P. 2011. *Diagnosis and management of adult congenital heart disease*. 3rd edition. Philadelphia: Saunders Elsevier.

Ho, SY, Rigby, ML, and Anderson, RH. 2005. *Echocardiography in congenital heart disease made simple*. 1st edition. London: Imperial College Press.

Li, W, West, C, McGhie, J, et al. 2018. Consensus recommendations for echocardiography in adults with congenital heart defects from the International Society of Adult Congenital Heart Disease (ISACHD). *Int J Cardiol.* **272**: 77–83.


[PMID: 30017529](#)

Warnes, CA, Williams, RG, Bashore, TM, et al. 2008. ACC/AHA 2008 Guidelines for the Management of Adults with Congenital Heart Disease: a report of the American College of Cardiology/American Heart Association Task Force on Practice Guidelines (writing committee to develop guidelines on the management of adults with congenital heart disease). *Circulation.* **118**: e714–e833.

[PMID: 18997169](#)

## Chapter 2

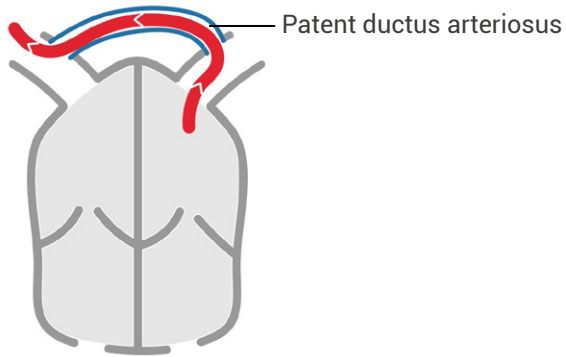
# SIMPLE SHUNTS



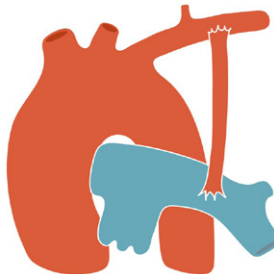
# Simple shunts

A shunt refers to an abnormal pathway of blood and in cardiology, describes one of two situations.

1. A congenital shunt—this can be a hole such as a septal defect, an anomalous pathway such as a patent ductus arteriosus or an anomalous pulmonary vein.



2. An iatrogenic shunt—a conduit which has been surgically implanted to create an additional pathway. This is usually to encourage blood flow, to stimulate the growth of vessels such as the pulmonary arteries via Blalock-Taussig shunt placement or to facilitate the mixing of blood.



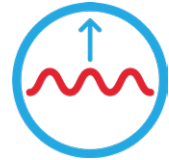Shunts can be multiple or associated with other (sometimes very complicated) defects. Not all shunts are bad. In complex congenital heart disease, survival can depend on having a shunt—an example of this is transposition of the great arteries.

In this chapter, simple shunts are the focus—that is, shunts which occur in isolation.

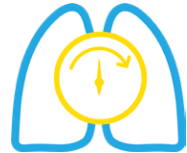### **Types of shunts covered**

- Atrial septal defects (ASD)
- Ventricular septal defects (VSD)
- Patent ductus arteriosus (PDA)

The physiology of the shunt depends very much on its location. However, all shunts result in increased blood flow through the pulmonary system.



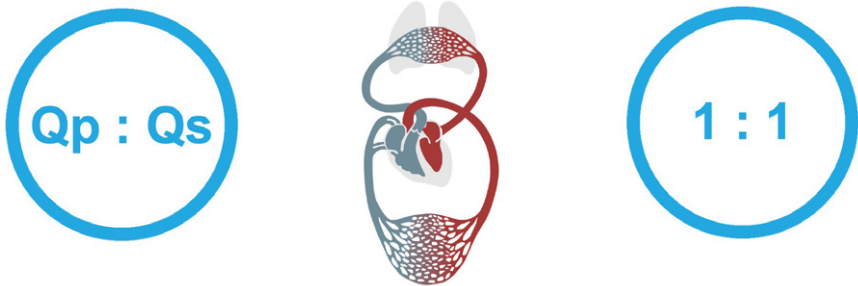
This can lead to changes in the pulmonary vascular system, which can subsequently lead to the onset of pulmonary hypertension.



# Hemodynamics

## $Q_p : Q_s$

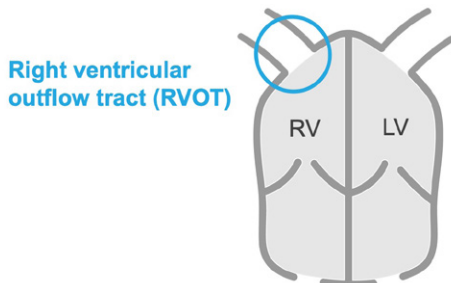
The increased flow through the pulmonary system is expressed throughout cardiology as a ratio of pulmonary flow ( $Q_p$ ) to systemic flow ( $Q_s$ ). A  $Q_p : Q_s$  of 1 : 1 describes a normal circulation, where the flow through the pulmonary and systemic circuits is equal.



$Q_p$  and  $Q_s$  are calculated using the formula below.

**Stroke volume = cross sectional area (CSA) x flow**

With echo,  $Q_p$  is estimated using the stroke volume at the right ventricular outflow tract (RVOT).



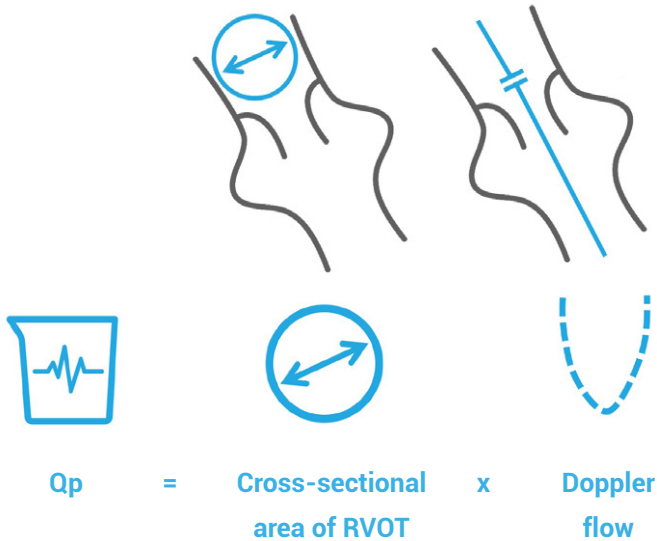


$$\text{CSA} = 0.785 \times \text{RVOT diameter}^2(\text{cm})$$

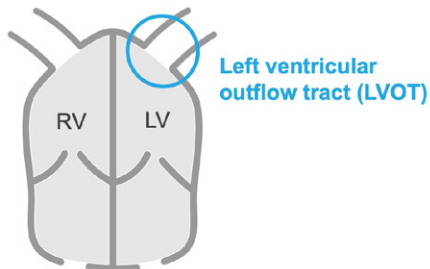
and

$$\text{flow} = \text{VTI (cm) measured at the RVOT}$$

For  $Q_p$ , measurements are completed in the parasternal short-axis view.



$Q_s$  uses the same formula but the stroke volume is measured at the left ventricular outflow tract (LVOT).

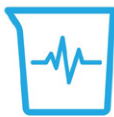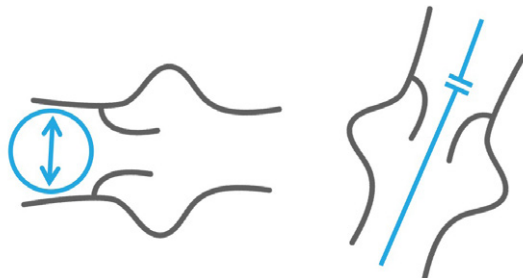


$$\text{CSA} = 0.785 \times \text{LVOT diameter}^2(\text{cm})$$

and

$$\text{flow} = \text{VTI (cm)} \text{ measured at the LVOT.}$$

For Qs, the parasternal short-axis view is used to obtain the diameter for calculating the cross-sectional area and the apical view is used to measure the flow, or VTI.



Qs

=



Cross-sectional  
area of LVOT

x



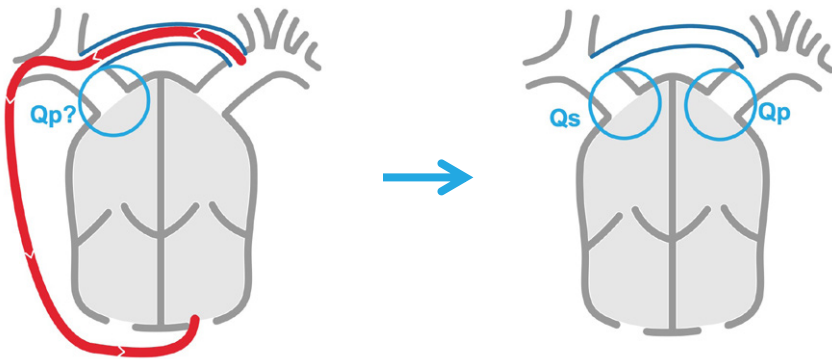
Doppler  
flow



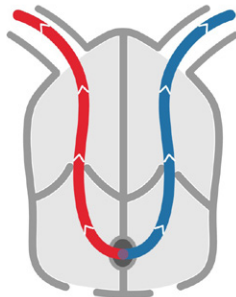
Where an ASD or VSD shunts left-to-right, there will be more flow in the pulmonary system. A small shunt might be 1.2 : 1 and a very large shunt might be 3 : 1. Shunts with a ratio greater than 1.5 are considered for closure.



*Calculating the  $Q_p : Q_s$  for a PDA is different because the PDA flow enters the pulmonary artery, which is beyond the point where we measure the pulmonary circulation. In PDA, the  $Q_p$  is measured at the LVOT and  $Q_s$  is measured at the RVOT.*

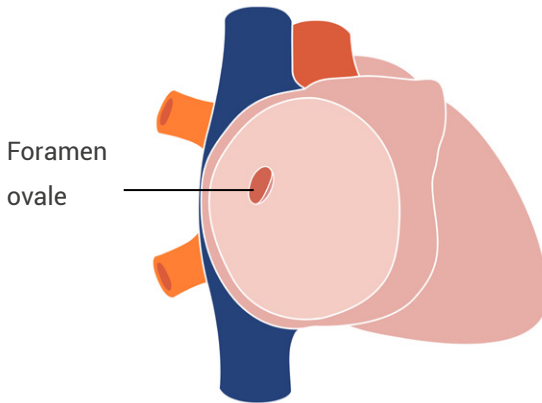


In Eisenmenger physiology, where pulmonary pressure = systemic pressure, it is likely the  $Q_p : Q_s$  will still be 1 : 1 because pressures have equalized. This does not mean the defect has closed or is not shunting at all, simply that both circuits are equally overloaded, as there is little or no pressure gradient to drive flow, so there is no net shunt. Look carefully at the defect with color flow—often these shunts are bidirectional.

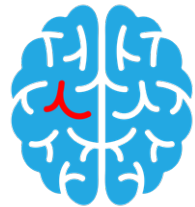

# Atrial septal defects

The atrial septum is the structure which lies between the upper chambers of the heart and separates the venous and systemic circulations. In the center there is a foramen ovale—a flap-like structure, which plays an important role in the fetal circulation. As oxygenated blood returning from the placenta enters the right atrium, the foramen ovale allows passage of blood across to the left atrium.

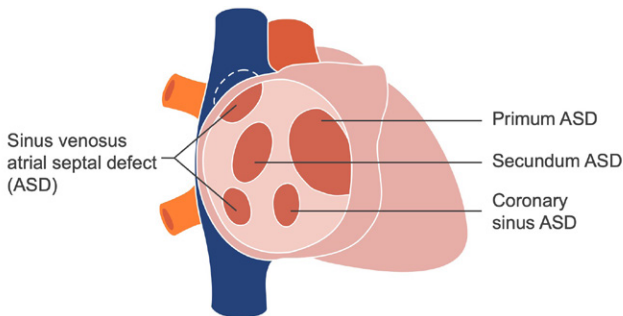


After the baby is born, several changes take place—the placenta is disconnected and the lungs become responsible for oxygenation. The foramen ovale is no longer required and closes in the first days of life in 90% of the population but in some people, it remains open (a patent foramen ovale) and is regarded as an increased risk factor for stroke.



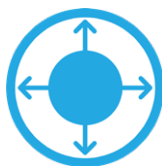
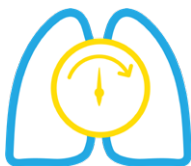The atrial septal flap is the key anatomical feature of a patent foramen ovale and the interatrial flow is often serpiginous. A patent foramen ovale is a normal structure, which failed to close.

Atrial septal defects, however, result from abnormal embryological development and are characterized by a true defect or hole in the atrial septum. The major types are demonstrated below.



All atrial septal defects result in increased volume in the right heart chambers and lungs, which may cause pulmonary hypertension. However, not all patients develop pulmonary hypertension and the reasons for the variable progression of pulmonary disease are not well understood at the present time.

Dilatation of the right atrium can predispose patients to arrhythmias.



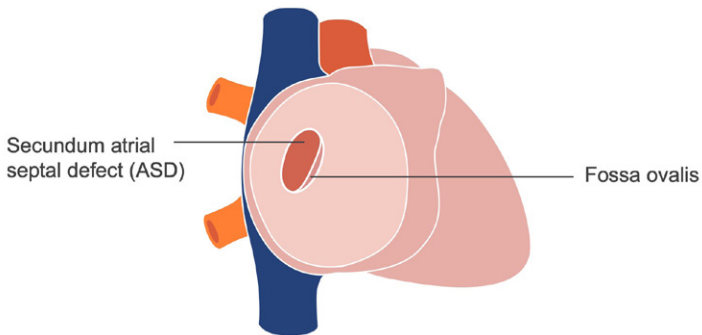
The primary indication for closure (either by surgery or device) is evidence of right ventricular volume loading seen on echo. This is seen as dilatation of the right ventricle and the hemodynamic lesion can be quantified by measuring the Qp : Qs. A Qp : Qs > 1.5 is regarded as an indication for closure.

### **Major points for echocardiography**

- Detection of atrial septal defect (location, size, direction of flow)
- Assessment of right ventricular size
- Assessment of pulmonary pressure
- Exclusion of associated defects

Accurate assessment of right ventricular size is important. Contraindication for closure is pulmonary artery systolic pressure (PASP) > 50% of systemic blood pressure, which is usually excluded invasively at the time of the closure, unless confounding evidence of pulmonary hypertension is demonstrated by echocardiography.

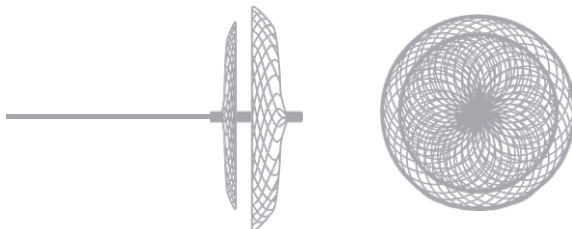
## Secundum atrial septal defect



The septum secundum describes the center of the atrial septum and is the most common type of ASD.

It is most commonly associated with mitral valve prolapse and pulmonary valvular stenosis.

Treatment options may include closure with a percutaneous occluder, performed in the cardiac catheter laboratory, usually with transesophageal echo guidance. Only defects which have an appropriate posterior rim are suitable, as the device requires adequate surrounding tissue for anchoring.



Percutaneous occlusion device

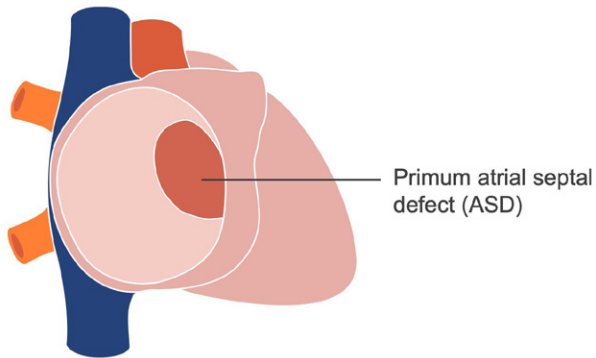
The anterior margin is not as crucial, as the device can hug the aorta and remain securely in position. Suitability for device closure is usually done by transesophageal echo, especially in cases where the rim is considered borderline; however, many definite inclusions or exclusions can be decided with expert transthoracic echo. A good command of spatial and image orientation is required for this.



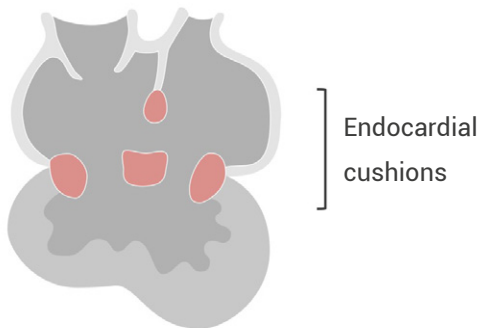*Where the rims are inadequate for occluder placement because the defect is very large or there are significant co-existing lesions, surgery may be considered. Small ASDs might be stitched together but for larger ASDs, a patch is often required.*



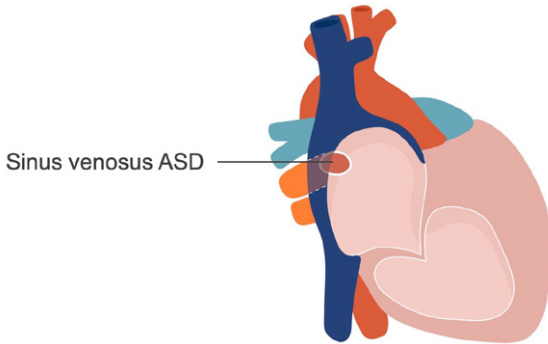
## Primum atrial septal defects



Primum defects occur in the ostium primum region, which is located inferiorly in the atrial septum, closest to the cardiac crux. They occur through a defect in embryologic development of the endocardial cushions and are one feature of a wider anomaly, atrioventricular septal defect. They will be discussed further in the chapter on atrioventricular septal defects.



## Sinus venosus atrial septal defects



Sinus venosus defects are posterior in the atrial septum and can be in close proximity to either the superior vena cava (SVC) or the inferior vena cava (IVC).

SVC-type defects are most commonly seen and often override the interatrial septum. They are also commonly associated with partial anomalous pulmonary venous drainage.



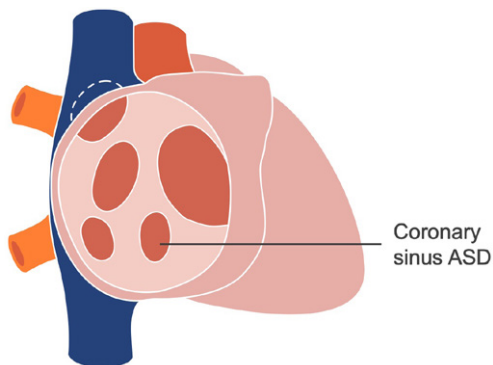
*The indication for treatment is dilatation of the right heart chamber and at this time, can only be performed by surgical intervention.*

### The surgery has two components

1. The defect is closed, to stop the mixing of blood, by routing the SVC flow directly into the right atrium.
2. The anomalous pulmonary vein is re-routed to the left atrium.

Postoperative complication can include a degree of superior vena cava obstruction, due to shrinkage of the baffle used to re-route the SVC.

## Coronary sinus atrial septal defects







The coronary sinus is a great vein, which runs posteriorly behind the left atrium in the atrioventricular groove. A coronary sinus defect allows venous blood, from the coronary sinus, to enter directly into the left atrium. Coronary sinus defects are associated with a persistent left superior vena cava.

# Ventricular septal defects

The ventricular septum is a predominantly muscular wall, which separates the lower chambers of the heart. As the left ventricle has a very high pressure and the right ventricle has significantly lower pressure, the septum usually curves towards the right ventricle and also spirals as it guards both inflow and outflow tracts. The ventricular septum is divided into four zones and defects are named after the zones.

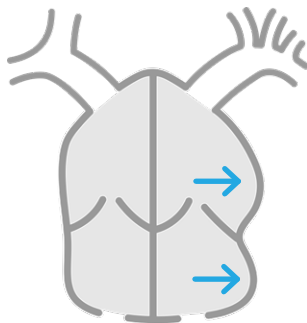
Nomenclature for ventricular septal defects (VSDs) can be confusing, as multiple terms are used.

	<b>Zone</b>	<b>Also known as</b>
	<b>Inlet</b>	AVSD-type, AV canal, perimembranous inlet
	<b>Perimembranous</b>	Membranous, paramembranous, conoventricular, subaortic, infracristal
	<b>Muscular</b>	Trabecular, apical
	<b>Outlet</b>	Conal, juxta-arterial, doubly committed, supracristal, subarterial, sub-pulmonary

All types of VSD result from abnormalities in embryologic development. It is possible that when diagnosed in childhood, small VSDs can spontaneously close but this usually occurs before approximately five years of age.



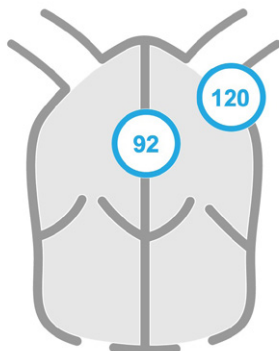
Like ASDs, VSDs also result in increased flow to the pulmonary system, which can cause long-term damage and progress into pulmonary hypertension. Unlike ASDs, VSD volume loading is seen as dilatation of the left atrium first and progresses to the left ventricle. Right heart dilatation only comes with the development of pulmonary hypertension.



Left heart dilatation

Echocardiography provides an excellent tool to assess VSDs, as it is able to provide both anatomic and hemodynamic information.

The pressure difference in the two ventricles is usually very high in systole; therefore, the VSD will have a high velocity systolic jet. In echo, we convert the velocity into a pressure gradient, as depicted by the 92 in the image below.



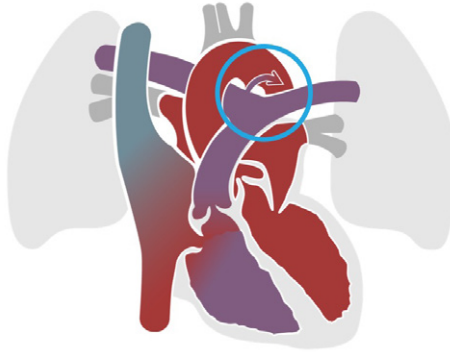When the systolic blood pressure is taken at the time of the echo, the blood pressure, minus the VSD jet, can be used to calculate the right ventricular systolic pressure. In the absence of right ventricular outflow obstruction, this can be used as a surrogate for pulmonary pressure, to exclude pulmonary hypertension.

$$\text{RVSP (mmHg)} = \text{systolic BP} - \text{VSD gradient}$$

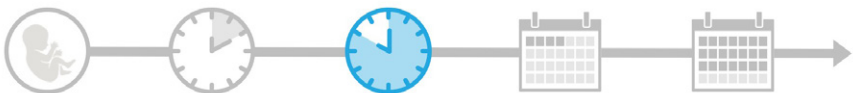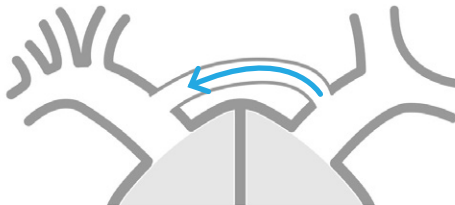Perimembranous VSDs have high velocity flow crossing the septum in close proximity to the aortic valve and aortic regurgitation can result from the Venturi effect, which manifests as prolapse of the right coronary cusp. The detection of any degree of aortic regurgitation is significant and prompts intervention in order to save the valve from further degeneration.

# Patent ductus arteriosus

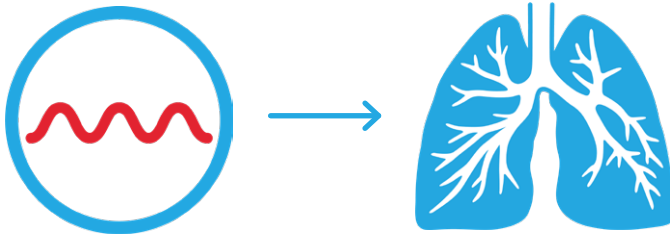
The ductus arteriosus is a normal structure with an important role in fetal circulation, to divert blood away from the pulmonary arteries (as the lungs are not in use in utero) and direct it toward the aorta.



Before birth, the pulmonary vascular resistance is very high and flow across the ductus is from right-to-left to encourage flow into the systemic circulation.

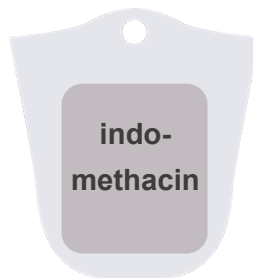

At birth, the lungs inflate immediately, as the baby takes its first breath. As they become responsible for oxygenation, it is important that blood, from the pulmonary arteries, is directed towards the lungs. Rapid hormonal changes promote closure of the ductus arteriosus and the pulmonary vascular resistance continues to fall over the next few days.



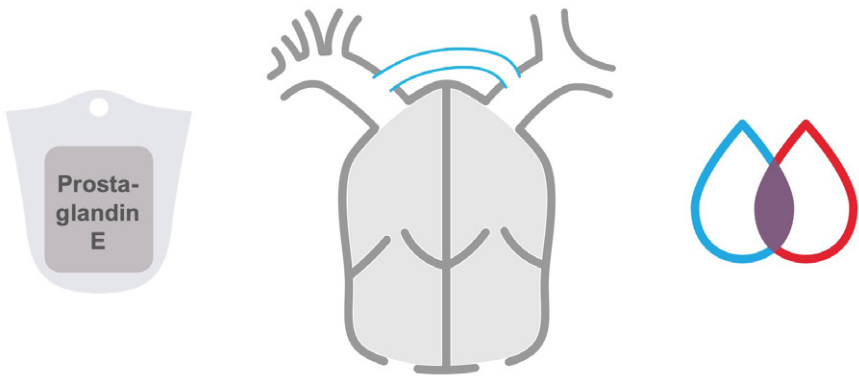
In some people, the ductus arteriosus fails to close. After the neonatal period, when pulmonary vascular resistance has fallen, the blood flows from the high pressure descending aorta into the lower pressure pulmonary artery and volume loads the lungs and the left side of the heart.

Patent ductus arteriosus is common in premature babies and in some situations closure of the ductus can be fast-tracked with administration of indomethacin.





However, in cases of complex congenital heart disease, the ductus arteriosus can play a life-saving role, by encouraging mixing of circulations (as in transposition) or an alternative pathway for blood to reach the descending aorta (as in interrupted aortic arch) and it may be beneficial to stop or even reverse the closure of the ductus. In this event, prostaglandin E1 can be administered, to keep the ductal communication open.



## Further reading

Alonso-González, R, Dimopoulos, K, Oliver, JM, et al. 2010. The right heart and pulmonary circulation (IX). The right heart in adults with congenital heart disease. *Rev Esp Cardiol.* **63**: 1070–1086.

[PMID: 20804703](#)

Baumgartner, H, Bonhoeffer, P, De Groot, NM, et al. 2010. ESC Guidelines for the management of grown-up congenital heart disease (new version 2010). *European Heart Journal.* **23**: 2915–2957.

[PMID: 20801927](#)

Deri, A and English, K. 2018. Educational Series in Congenital Heart Disease: Echocardiographic assessment of left to right shunts: atrial septal defect, ventricular septal defect, atrioventricular septal defect, patent arterial duct. *Echo Res Pract.* **5**: R1–R16.

[PMID: 29432197](#)

Di Salvo, G, Miller, O, Babu Narayan, S, et al. 2018. Imaging the adult with congenital heart disease: a multimodality imaging approach–position paper from the EACVI. *Eur Heart J Cardiovasc Imaging.* **19**: 1077–1098.

[PMID: 30084968](#)

Eidem, BW, Cetta, F, and O'Leary PW. 2010. *Echocardiography in pediatric and adult congenital heart disease.* **2nd edition.** Philadelphia: Lippincott Williams & Wilkins.

Gatzoulis, M, Webb, G, and Daubeney, P. 2011. *Diagnosis and management of adult congenital heart disease.* 3rd edition. Philadelphia: Saunders Elsevier.

Ho, SY, Rigby, ML, and Anderson, RH. 2005. *Echocardiography in congenital heart disease made simple.* 1st edition. London: Imperial College Press.

Li, W, West, C, McGhie, J, et al. 2018. Consensus recommendations for echocardiography in adults with congenital heart defects from the International Society of Adult Congenital Heart Disease (ISACHD). *Int J Cardiol.* **272**: 77–83.

[PMID: 30017529](#)

Simpson, J, Lopez, L, Acar, P, et al. 2016. Three-dimensional echocardiography in congenital heart disease: an expert consensus document from the European Association of Cardiovascular Imaging and the American Society of Echocardiography. *Eur Heart J Cardiovasc Imaging*. **17**: 1071–1097.

[PMID: 27655864](#)

Warnes, CA, Williams, RG, Bashore, TM, et al. 2008. ACC/AHA 2008 Guidelines for the Management of Adults with Congenital Heart Disease: a report of the American College of Cardiology/American Heart Association Task Force on Practice Guidelines (writing committee to develop guidelines on the management of adults with congenital heart disease). *Circulation*. **118**: e714–e833.

[PMID: 18997169](#)

Webb, G and Gatzoulis, MA. 2006. Atrial septal defects in the adult: recent progress and overview. *Circulation*. **114**: 1645–1653.

[PMID: 17030704](#)

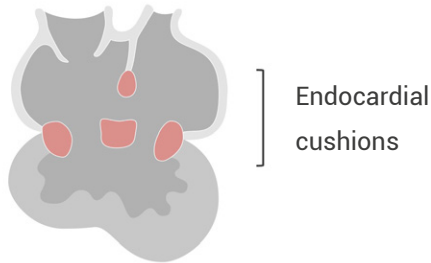## Chapter 3

# ATRIOVENTRICULAR SEPTAL DEFECTS



# Atrioventricular septal defects

The normal formation of the intracardiac crux stems from complex development of the endocardial cushions. The cushions develop and grow to form the atrioventricular junction and valves, the primum atrial septum, and the inlet portion or crest of the ventricular septum.

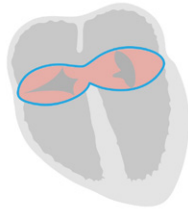

## **Abnormal development of this region is known by several names**

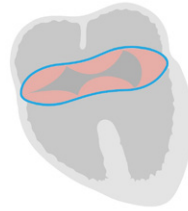- Atrioventricular septal defect
- Endocardial cushion defect
- Atrioventricular canal defect
- Primum atrial septal defect with a cleft mitral valve
- Inlet ventricular septal defect

The variability of abnormal development of the atrioventricular region is quite large. For simplicity, we have just shown the extremes of partial and complete but transitional and intermediate atrioventricular septal defects (AVSDs) also exist in the spectrum between partial and complete AVSD. Like partial, they both contain a piece of tissue that separates the common atrioventricular valve.

The most common types of AVSD are partial and complete.



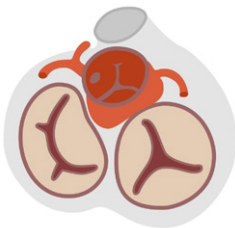
Partial



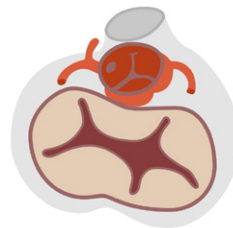
Complete

### Common features to both partial and complete AVSDs

- Primum atrial septal defect (ASD)
- Single AV junction
- Abnormal atrioventricular septal valve leaflets (both in formation and lack of tricuspid valve offset)
- Unwedged aorta (displaced by common AV junction—pushed more anteriorly—results in an elongated left ventricular outflow tract, increases chance of left ventricular outflow obstruction)



Normal



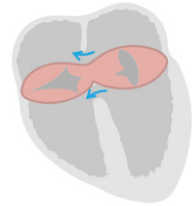
Complete AVSD (unwedged aorta)

- Increased blood flow to pulmonary system (potential to develop into Eisenmenger physiology if untreated)
- Association with Down syndrome

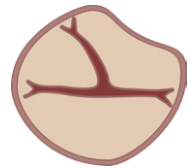
# Partial atrioventricular septal defect

## Partial AVSD is characterized by

- Primum ASD
- Single AV junction
- No offset of AV leaflets
- Partial fusion of AV leaflets (two separate orifices)



This results in a trileaflet left AV valve (often referred to as a cleft mitral valve), formed from one posterior leaflet and two partially fused anterior leaflets—as shown in the diagram to the right.



When the left atrioventricular valve shares the AV junction with the right AV valve it appears trileaflet and has abnormal papillary muscle structure, it is often referred to as a left AV valve rather than a mitral valve.

Partial AVSD is also referred to as a primum ASD with cleft mitral valve.

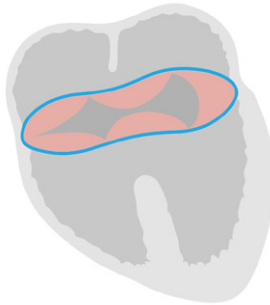## **Corrective surgery**

- ASD (and VSD if present) is patched closed
- Anterior leaflets of left AV valve are sutured together
- Annuloplasty ring may be added (if required)

# Complete atrioventricular septal defect

## Complete AVSD is characterized by

- Primum ASD
- Single AV junction
- Single AV valve (usually with five leaflets opening to both ventricles)
- Inlet ventricular septal defect (VSD)
- Displacement of AV node (not seen on echo)



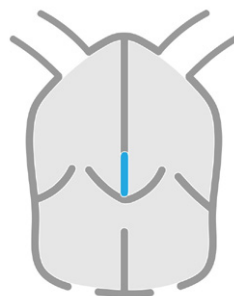
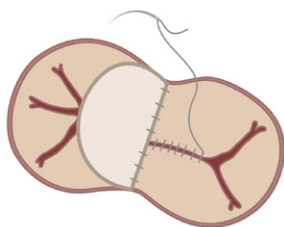
## Preoperative assessment should include

- Differentiation of partial versus complete AVSD
- Determination of location and size of defect
- Degree of AV valvular regurgitation
- Particular attention paid to AV chordae (ensure insertion into appropriate ventricle and do not cross VSD—key feature in the determination of suitability for two ventricle repair)
- Assess right ventricular size and function
- Estimation of pulmonary artery pressure



## **Corrective surgery**

- Strategy is based on associated lesions (e.g., isomerisms, double outlet right ventricle)
- Complex AV chordal insertions may require single ventricle repair (Fontan circulation)
- Two patch technique is one type of biventricular repair
- Postoperative complications (e.g., regurgitation or stenosis of repaired valve, patch leaks or development of pulmonary hypertension)



## Further reading

Alonso-González, R, Dimopoulos, K, Oliver, JM, et al. 2010. The right heart and pulmonary circulation (IX). The right heart in adults with congenital heart disease. *Rev Esp Cardiol*. **63**: 1070–1086.

[PMID: 20804703](#)

Baumgartner, H, Bonhoeffer, P, De Groot, NM, et al. 2010. ESC Guidelines for the management of grown-up congenital heart disease (new version 2010). *European Heart Journal*. **23**: 2915–2957.

[PMID: 20801927](#)

Deri, A and English, K. 2018. Educational Series in Congenital Heart Disease: Echocardiographic assessment of left to right shunts: atrial septal defect, ventricular septal defect, atrioventricular septal defect, patent arterial duct. *Echo Res Pract*. **5**: R1–R16.

[PMID: 29432197](#)

Di Salvo, G, Miller, O, Babu Narayan, S, et al. 2018. Imaging the adult with congenital heart disease: a multimodality imaging approach–position paper from the EACVI. *Eur Heart J Cardiovasc Imaging*. **19**: 1077–1098.

[PMID: 30084968](#)

Eidem, BW, Cetta, F, and O'Leary PW. 2010. *Echocardiography in pediatric and adult congenital heart disease*. 2nd edition. Philadelphia: Lippincott Williams & Wilkins.

Gatzoulis, M, Webb, G, and Daubeney, P. 2011. *Diagnosis and management of adult congenital heart disease*. 3rd edition. Philadelphia: Saunders Elsevier.

Ho, SY, Rigby, ML, and Anderson, RH. 2005. *Echocardiography in congenital heart disease made simple*. 1st edition. London: Imperial College Press.

Li, W, West, C, McGhie, J, et al. 2018. Consensus recommendations for echocardiography in adults with congenital heart defects from the International Society of Adult Congenital Heart Disease (ISACHD). *Int J Cardiol.* **272**: 77–83.

[PMID: 30017529](#)

Simpson, J, Lopez, L, Acar, P, et al. 2016. Three-dimensional echocardiography in congenital heart disease: an expert consensus document from the European Association of Cardiovascular Imaging and the American Society of Echocardiography. *Eur Heart J Cardiovasc Imaging.* **17**: 1071–1097.

[PMID: 27655864](#)

Warnes, CA, Williams, RG, Bashore, TM, et al. 2008. ACC/AHA 2008 Guidelines for the Management of Adults with Congenital Heart Disease: a report of the American College of Cardiology/American Heart Association Task Force on Practice Guidelines (writing committee to develop guidelines on the management of adults with congenital heart disease). *Circulation.* **118**: e714–e833.

[PMID: 18997169](#)

## Chapter 4

# LEFT VENTRICULAR OUTFLOW LESIONS



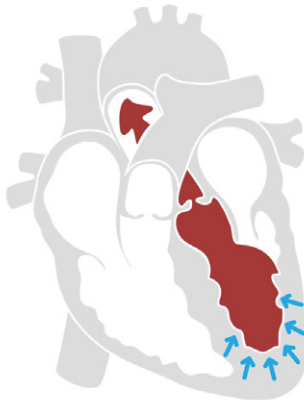# Left ventricular outflow lesions

In this chapter, we cover left ventricular outflow tract (LVOT) obstruction, from ventricular level through to the descending aorta.

## This includes the following lesions

- Dynamic LVOT obstruction (as seen in hypertrophic cardiomyopathy)
- Fixed LVOT obstruction (as seen in subaortic membrane)
- Valvular stenosis
- Supravalvular stenosis
- Coarctation of aorta

All of these obstructions increase the afterload for the left ventricle, which can lead to systolic dysfunction and ventricular remodeling if left untreated.



# Dynamic left ventricular outflow tract obstruction

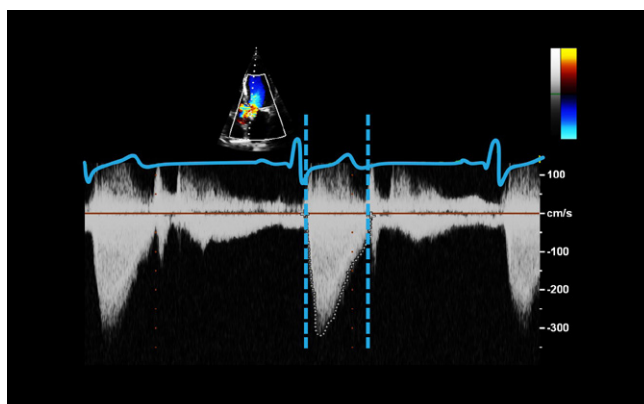
**Dynamic left ventricular outflow tract (LVOT) obstruction, as in hypertrophic cardiomyopathy, is highly sensitive to preload or filling of the left ventricle.**

- Septal thickening creates a structural issue, which predisposes the ventricle to outflow obstruction, by intrinsically narrowing the outflow tract.
- The narrowing can cause flow acceleration, creating a Venturi effect, which sucks the mitral valve leaflets into the outflow tract. This is called systolic anterior motion (SAM) of the mitral valve.
- Reduced preload results in less volume in the left ventricle, which reduces the left ventricular cavity size. This effectively reduces the LVOT further and potentially magnifies the effect of either the septal thickening or the systolic anterior motion of the mitral valve leaflets.
- As well as obstructing the outflow tract, the SAM interferes with normal mitral valve function and can result in significant mitral regurgitation.
- Performing the Valsalva maneuver reduces the preload quickly and can be used to provoke gradients, which may not occur at rest. This is done to simulate daily activities such as lifting or straining.



# Fixed left ventricular outflow tract obstruction

Fixed left ventricular outflow tract (LVOT) obstructions can result from either a subaortic membrane or ridge (discrete narrowings) or a small LVOT creating a tunnel-like obstruction. Fixed obstructions are not as sensitive to preload as dynamic obstructions. The obstructions are always present, therefore, the Doppler peaks early in systole.

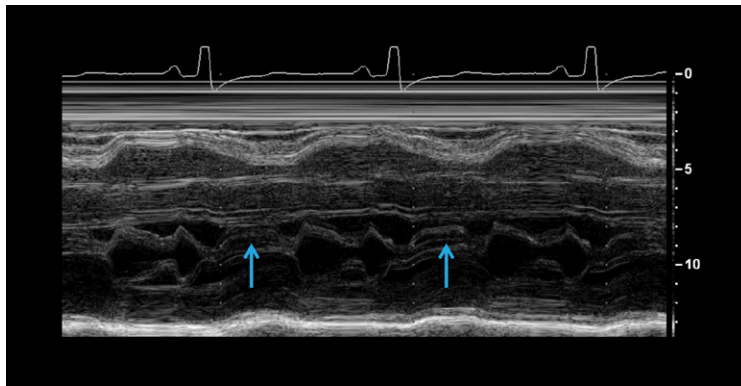


The increased velocity of the blood cells often damages the very thin aortic valve leaflets, this can result in thickening or fibrosis and aortic regurgitation.

Differentiating LVOT obstruction from valvular stenosis has important implications for patient management, so appropriate choice of intervention can be made (e.g., balloon valvuloplasty is effective for valvular stenosis but not for LVOT obstruction).

## Timing is important

A key differentiator between dynamic left ventricular outflow tract (LVOT) obstruction and fixed obstructions is the timing. In early systole, there may be normal flow but towards mid-systole the SAM gets worse and simultaneously increases both the LVOT obstruction and the degree of mitral regurgitation. Both will have a distinctive late peaking, dagger-shaped signal.













# Valvular aortic stenosis

Bicuspid aortic valves are thought to be the most common type of congenital heart disease, seen in 1–2% of the general population. The main type of congenital malformations are described in the table below.

## Anatomy

Leaflets	Subtypes	Description	Diagram(s)
1	<b>Acommissural</b>	No raphe, pinhole opening	
	<b>Unicommissural</b>	Slit-like opening	
2	<b>True-0a</b>	0 raphes, 2 sinuses, 1 coronary artery per sinus	
	<b>True-0b</b>	0 raphes, 2 sinuses, both coronary arteries from same sinus	
	<b>Functional</b>	1 raphe, 3 sinuses	
	<b>Functional</b>	2 raphes, 3 sinuses	
3	<b>Dysplasia</b>	Malformed retracted leaflets	
4	<b>I-IV</b>	Symmetric or asymmetric leaflet distribution	

## Clinical implications

All congenitally abnormal aortic valves have significant clinical sequela, or consequences, that nearly always require intervention.

**This can be split into four categories**

### 1. Valve dysfunction

- stenosis
- regurgitation

### 2. Increased risk of endocarditis

### 3. Aortopathy

- aortic root dilatation
- aortic dissection
- coarctation of aorta

### 4. Syndromes

- bicuspid valves are more prevalent in Turner and Marfan syndrome patients

## Hemodynamics

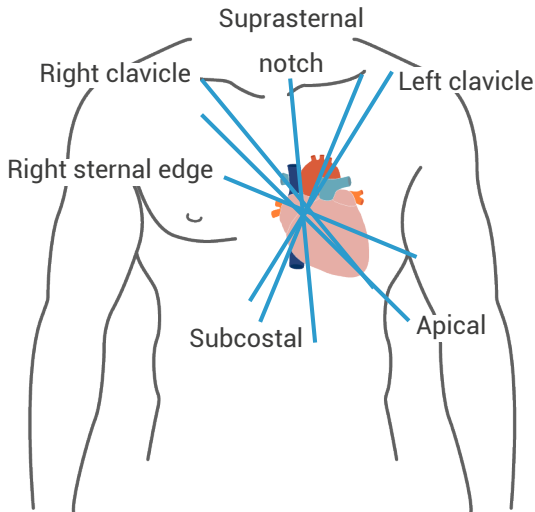
Echo is the ideal tool to follow the hemodynamics of patients with valvular stenosis, due to its ability to delineate the anatomy and to assess the degree of obstruction, co-existing lesions, and impact on the left ventricle.

The severity of aortic stenosis is calculated by determining the valve gradients and the effective orifice area (EOA).

# Valve gradients

The Doppler gradient is calculated using continuous wave (CW) Doppler to detect the maximal Doppler shift. By tracing the Doppler signal, the peak instantaneous gradient and mean gradient, can be estimated. This calculation relies heavily on having the ultrasound beam parallel to flow; therefore, multiple locations around the chest and neck area (shown below) are used to achieve the best alignment.

Using a dedicated CW Doppler probe with a smaller footprint is beneficial, facilitating better access, dexterity, and alignment as well as a lower signal-to-noise ratio, which improves the detection of flow.



Aortic valve area (AVA) or effective orifice area, by continuity equation

$$\text{AVA (cm}^2\text{)} = \text{LVOT area} \times (\text{LVOT} \times \text{VTI}) / (\text{AoV} \times \text{VTI})$$

$$\text{LVOT area} = 0.785 \times \text{LVOT dimension}^2$$

LVOT x VTI = pressure wave Doppler trace

AoV VTI = aortic valve Doppler trace

Area calculations are important—by including the stroke volume (LVOT area x [LVOT x VTI]) they account for different hemodynamic states as the stroke volume varies, which has a direct impact on the aortic valve gradient. As ejection fraction (EF) falls, the gradient will also fall. This is particularly useful for patients with left ventricular dysfunction.

	<b>Aortic sclerosis</b>			
	<b>Mild</b>	<b>Moderate</b>	<b>Severe</b>	
Vmax (m / s)	< 2.5	2.6–2.9	3.0–4.0	≥ 4
Mean gradient (mmHg)	< 20	20–40		≥ 40
AVA (cm <sup>2</sup> )	> 1.5	1.0–1.5		≤ 1.0
Indexed AVA (cm <sup>2</sup> / m <sup>2</sup> )	> 0.85	0.6–0.85		< 0.6
Velocity ratio	> 0.5	0.25–0.50		< 0.25

(Reference: Baumgartner et al., 2017)

## Low-flow, low-gradient aortic stenosis

Gradients have traditionally been regarded as a reliable way to follow the progress of aortic stenosis (AS), but in recent years, research has shown there may be some confounding factors such as low-flow states. These have a powerful effect on gradients in situations where there is low-flow due to left ventricular dysfunction or paradoxical low-flow, as can be seen with small left ventricular cavities.

### The four categories of aortic stenosis

Category	Aortic valve area	Mean gradient	Ejection fraction	Indexed stroke volume
<b>High-gradient aortic stenosis</b>	< 1.0 cm <sup>2</sup>	≥ 40 mmHg	Independent	
<b>Low-flow, low-gradient as with reduced EF</b>	< 1.0 cm <sup>2</sup>	< 40 mmHg	< 50%	≤ 35 mL / m <sup>2</sup>
<b>Low-flow, low-gradient as with preserved EF</b>	< 1.0 cm <sup>2</sup>	< 40 mmHg	≥ 50%	≤ 35 mL / m <sup>2</sup>
<b>Paradoxical normal-flow, low-gradient as with preserved EF</b>	< 1.0 cm <sup>2</sup>	< 40 mmHg	≥ 50%	> 35 mL / m <sup>2</sup>



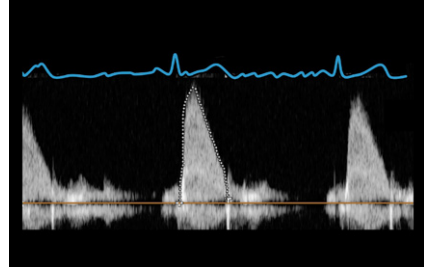
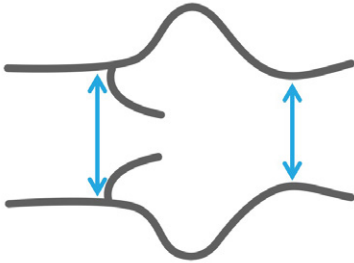
*Indexing the stroke volume to body surface area is a good way of identifying those patients who may benefit from stress echo. Patients with discrepant aortic data (where indexed stroke volume is  $\leq 35 \text{ mL} / \text{m}^2$ ) may benefit from a dobutamine stress echo to normalize the stroke volume.*

In pseudo aortic stenosis, the gradient will rise and the valve area will increase due to improved contractility, whereas in true aortic stenosis, the gradient will rise but the valve area will remain in the severe range.

**Normal indexed stroke volume  $> 35 \text{ mL} / \text{m}^2$**

# Supravalvular aortic stenosis

This usually occurs at the sinotubular junction or as tubular hypoplasia of the ascending aorta.



Ascending aorta

The discrete sinotubular junction variant can be difficult to see on echo but suspicion can be raised in the event of increased aortic velocities in the presence of a normally opening aortic valve. It is associated with Williams syndrome.

In the case of tubular hypoplasia, this will appear as an undersized ascending aorta. Echo is useful for assessing disease progression in this setting but a long tubular obstruction can cause problems with the gradient. The Bernoulli equation, used in echo, to convert a Doppler shift to a pressure gradient contains mathematical assumptions best suited to discrete stenosis and can be unreliable—overestimating the true severity.

Assessment of supravalvular aortic stenosis requires the same careful approach as valvular stenosis, using multiple transducer positions on the chest in order to obtain optimal alignment.

# Coarctation of the aorta

Coarctation of the aorta can occur anywhere in the arch or proximal descending aorta but just distal to the ligamentum arteriosum is the most common area. Coarctations can be discrete and very localized or hypoplastic like a long, tubular narrowing. They are strongly associated with bicuspid aortic valves.

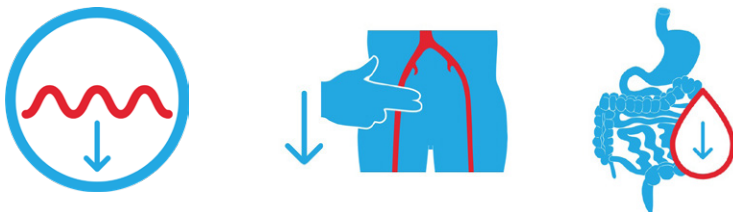
## Upstream effects proximal to the coarctation

- Increased LV afterload (possibly with LV hypertrophy)
- Increased blood pressure
- Increased cerebral pressure



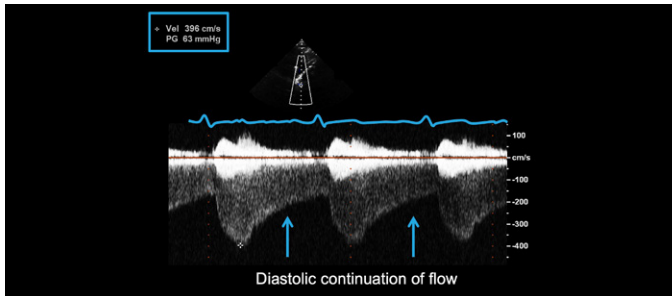
## Downstream effects distal to the coarctation

- Reduced blood flow
- Reduced femoral pulses (classic clinical sign)
- Reduced flow and risk of ischemia to visceral organs

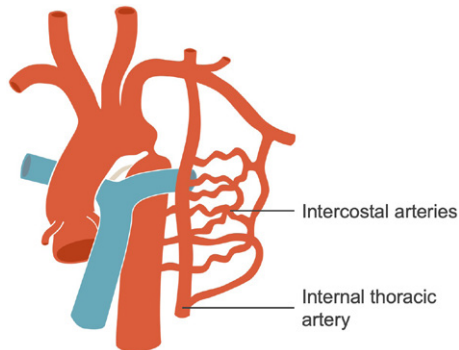




In a simple coarctation, there will be a discrete narrowing with a commensurate rise in velocity, reflecting the increased pressure gradient. Often the gradient continues into diastole, forming the classic Doppler sign of the diastolic continuation of flow, often referred to as the diastolic tail.



In more significant cases of coarctation, this diastolic continuation of flow can also be demonstrated in the abdominal aorta, from the subcostal view.



In cases of severe coarctation, collateral or intercostal vessels may form, which usually carry minimal amounts of flow, may significantly dilate, and can form an alternate pathway for flow to pass to the lower body, relieving the pressure in the upper body.

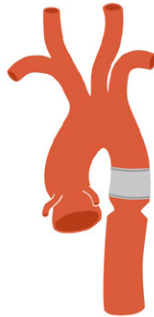The collateral vessels can compensate so well that there can be very little gradient at the coarctation site; therefore, gradient alone should not be used to confirm the diagnosis.

## Coarctation repair

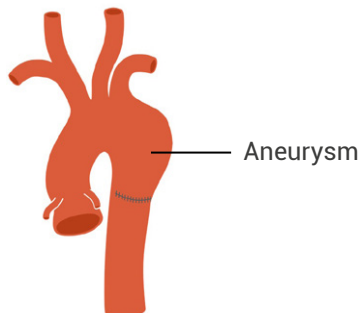
There are many different methods utilized to treat coarctation using both percutaneous or surgical approaches.

### The most common findings post-repair

- Re-stenosis at or near repair site



- Dilatation at or near repair site



## Further reading

Alonso-González, R, Dimopoulos, K, Oliver, JM, et al. 2010. The right heart and pulmonary circulation (IX). The right heart in adults with congenital heart disease. *Rev Esp Cardiol.* **63**: 1070–1086.

[PMID: 20804703](#)

Baumgartner, H, Bonhoeffer, P, De Groot, NM, et al. 2010. ESC Guidelines for the management of grown-up congenital heart disease (new version 2010). *European Heart Journal.* **23**: 2915–2957.

[PMID: 20801927](#)

Baumgartner, H, Falk, V, Bax, JJ, et al. 2017. 2017 ESC/EACTS Guidelines for the management of valvular heart disease. *Eur Heart J.* **38**: 2739–2791.

[PMID: 28886619](#)

Carr, M, Curtis, S, and Marek, J. 2018. Congenital left-sided heart obstruction. *Echo Res Pract.* pii: ERP-18-0016.

[PMID: 29549184](#)

Di Salvo, G, Miller, O, Babu Narayan, S, et al. 2018. Imaging the adult with congenital heart disease: a multimodality imaging approach–position paper from the EACVI. *Eur Heart J Cardiovasc Imaging.* **19**: 1077–1098.

[PMID: 30084968](#)

Eidem, BW, Cetta, F, and O'Leary PW. 2010. *Echocardiography in pediatric and adult congenital heart disease*. 2nd edition. Philadelphia: Lippincott Williams & Wilkins.

Gatzoulis, M, Webb, G, and Daubeney, P. 2011. *Diagnosis and management of adult congenital heart disease*. 3rd edition. Philadelphia: Saunders Elsevier.

Ho, SY, Rigby, ML, and Anderson, RH. 2005. *Echocardiography in congenital heart disease made simple*. 1st edition. London: Imperial College Press.

Li, W, West, C, McGhie, J, et al. 2018. Consensus recommendations for echocardiography in adults with congenital heart defects from the International Society of Adult Congenital Heart Disease (ISACHD). *Int J Cardiol.* **272**: 77–83.

[PMID: 30017529](#)

Nakamura Y, Taniguchi, I, Saiki, M, et al. 2001. Quadricuspid aortic valve associated with aortic stenosis and regurgitation. *Jpn J Thorac Cardiovasc Surg.* **49**: 714–716.

[PMID: 11808094](#)

Sievers, HH and Schmidtke, C. 2007. A classification system for the bicuspid aortic valve from 304 surgical specimens. *J Thorac Cardiovasc Surg.* **133**: 1226–1233.

[PMID: 17467434](#)

Warnes, CA, Williams, RG, Bashore, TM, et al. 2008. ACC/AHA 2008 Guidelines for the Management of Adults with Congenital Heart Disease: a report of the American College of Cardiology/American Heart Association Task Force on Practice Guidelines (writing committee to develop guidelines on the management of adults with congenital heart disease). *Circulation.* **118**: e714–e833.

[PMID: 18997169](#)

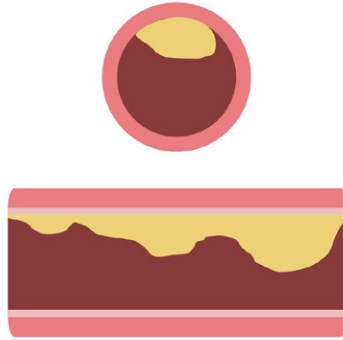
## Chapter 5

# CORONARY ARTERY DISEASE



# Coronary disease

Coronary artery disease in adults usually results from a build up of atherosclerotic plaque, which might be due to lifestyle factors or family history but coronary disease also affects children.

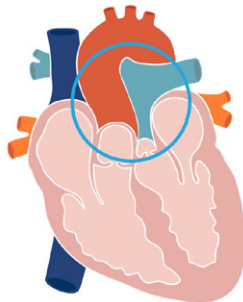


# Congenital anomalies

There are several variations of congenitally abnormal coronary arteries. These relate either to anomalous origin or vessel course. Some anomalies can remain innocent while others are clinically significant.

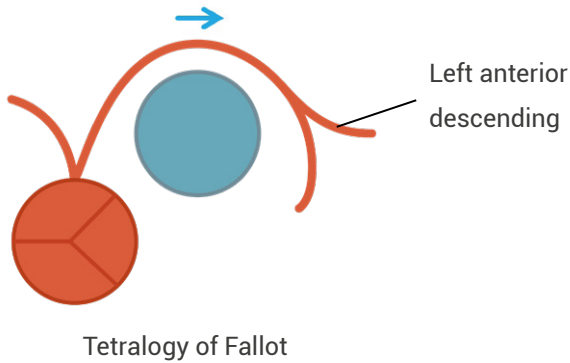
Coronary artery anatomy is an important consideration when planning surgical intervention, particularly for conditions such as transposition of the great arteries and in Tetralogy of Fallot.

Transposition of the great arteries is a form of ventriculoarterial discordance but coronary anomalies are a known associated defect. An anomalous circumflex artery is the most common coronary anomaly in this constellation. Translocation of the coronary arteries is a major component of the arterial switch operation and where coronary anatomy is not suitable, other types of repair will be considered.

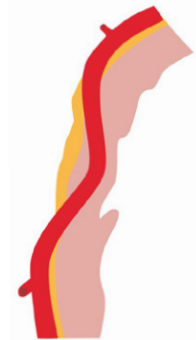


Tetralogy of Fallot is associated with anomalous left anterior descending arising from the right coronary artery and taking an anterior course in front of the right ventricular outflow tract or main pulmonary artery.

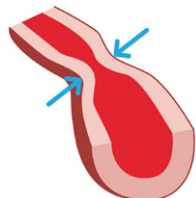
This has major implications for surgery, therefore, this area must be avoided. In these situations, an extracardiac conduit is inserted to avoid surgical incisions in the RVOT / main pulmonary artery area. This leaves the native stenosis but provides an alternative (and secondary) pathway from the right ventricle to the pulmonary artery.



Other coronary anomalies can involve unusual locations of the coronary artery like myocardial bridging, where the coronary artery deviates from the epicardium and lies deeper within the muscle wall. This affects the myocardial blood supply because as the muscle contracts in systole, it thickens and compresses the artery, temporarily interrupting the blood flow. While this might be okay at rest, during periods of stress, it can induce ischemia.



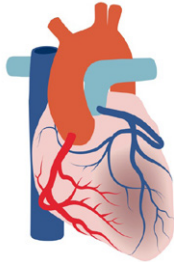
Coronary spasm can also affect children.





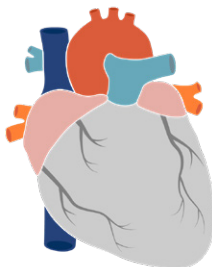
# Anomalous left coronary artery from the pulmonary artery

One example of a dangerous coronary artery anomaly is anomalous left coronary artery from the pulmonary artery (ALCAPA)—a life-threatening anomaly if left untreated. ALCAPA is also known as Bland-White-Garland syndrome, after three doctors who reported a case of ALCAPA in 1933.

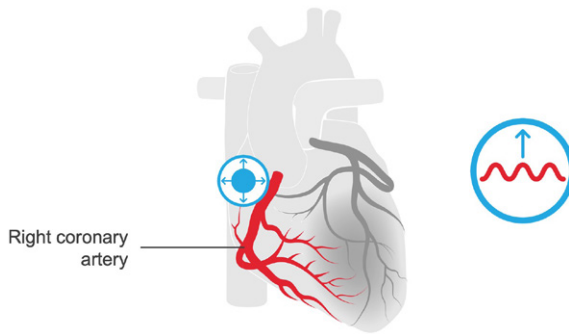


80–90%

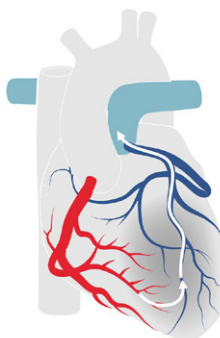
As the left coronary artery arises from the pulmonary artery, it is filled with deoxygenated blood. In the early neonatal period, pulmonary vascular resistance and pulmonary pressures are still elevated, so there is a good flow of blood into the coronary artery, albeit deoxygenated. As the pulmonary vascular resistance starts to fall, there is less driving force and less blood volume to fill the coronary artery, which results in myocardial ischemia, particularly during periods of stress such as crying or feeding.



The right coronary artery functions normally during this period, however, with increasing ischemia collateral vessels develop to take extra blood supply to the areas normally supplied by the left coronary artery. The right coronary artery typically dilates to accommodate the increased blood volume.



Coronary steal syndrome occurs when the collateral vessels start to drain into the left coronary artery—the pressure differential is such that the oxygen-rich blood flow drains into the main pulmonary artery. This drains oxygen-rich blood flow away from the ischemic muscle, further exacerbating the ischemia and likely resulting in chest pain.



The chronic ischemia causes heart failure and can cause a myocardial infarction. With echocardiography, unusual areas of echobright fibrosis or calcification might be seen on the subvalvular apparatus of the mitral valve or along the endocardium itself. The presence of mild or more mitral regurgitation or regional wall motion abnormalities are secondary features, which should prompt close inspection of the coronary arteries. Any of these features should be considered in context of the patient's age, as the echo appearance of the heart starts to appear older than the patient.

The right coronary artery ostia might be dilated. In some cases, it is possible to visualize the left coronary artery arising from the pulmonary artery itself or it might be possible to see the coronary flow draining into the pulmonary artery (coronary steal syndrome).




*Careful inspection, using a high parasternal short-axis view, at the level of the pulmonary artery bifurcation is often useful.*

# Kawasaki disease


Systemic diseases like Kawasaki disease can cause arteritis or inflammation of the arteries including the coronary arteries.

**Kawasaki disease is a tricky clinical diagnosis and usually has the following features**

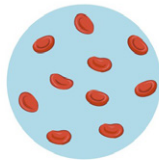
- Fever
- Rash on torso
- Bloodshot eyes
- Strawberry tongue



Blood tests show an increased white cell count, anemia, and an increased erythrocyte sedimentation rate.



White cells

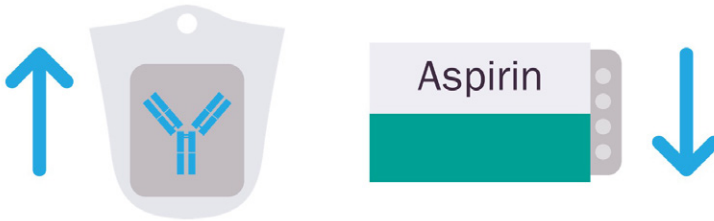

Anemia



Increased erythrocyte sedimentation rate

Treatment involves high-dose IV gamma globulin within the first ten days and subsequent low-dose aspirin, to minimize or prevent any long-term sequela.



Echo can be used for assessing the coronary arteries in children. Kawasaki affects the coronary arteries by inducing swelling of the walls, usually dilatation and multiple aneurysms can be seen on echo. Residual cardiac defects may follow such as dilated cardiomyopathy or the development of regional wall motion abnormalities, which can affect systolic function of the left ventricle.

Stress echo has incremental benefits for assessing the presence of ischemia, as wall motion abnormalities precede ECG changes in the ischemic cascade.

### ***Progression to ischemia***



## Further reading

Alonso-González, R, Dimopoulos, K, Oliver, JM, et al. 2010. The right heart and pulmonary circulation (IX). The right heart in adults with congenital heart disease. *Rev Esp Cardiol.* **63**: 1070–1086.

[PMID: 20804703](#)

Baumgartner, H, Bonhoeffer, P, De Groot, NM, et al. 2010. ESC Guidelines for the management of grown-up congenital heart disease (new version 2010). *European Heart Journal.* **23**: 2915–2957.

[PMID: 20801927](#)

Di Salvo, G, Miller, O, Babu Narayan, S, et al. 2018. Imaging the adult with congenital heart disease: a multimodality imaging approach–position paper from the EACVI. *Eur Heart J Cardiovasc Imaging.* **19**: 1077–1098.

[PMID: 30084968](#)

Eidem, BW, Cetta, F, and O'Leary PW. 2010. *Echocardiography in pediatric and adult congenital heart disease*. 2nd edition. Philadelphia: Lippincott Williams & Wilkins.

Gatzoulis, M, Webb, G, and Daubeney, P. 2011. *Diagnosis and management of adult congenital heart disease*. 3rd edition. Philadelphia: Saunders Elsevier.

Ho, SY, Rigby, ML, and Anderson, RH. 2005. *Echocardiography in congenital heart disease made simple*. 1st edition. London: Imperial College Press.

Li, W, West, C, McGhie, J, et al. 2018. Consensus recommendations for echocardiography in adults with congenital heart defects from the International Society of Adult Congenital Heart Disease (ISACHD). *Int J Cardiol.* **272**: 77–83.

[PMID: 30017529](#)

Pérez-Pomares, JM, de la Pompa, JL, Franco, D, et al. 2016. Congenital coronary artery anomalies: a bridge from embryology to anatomy and pathophysiology—a position statement of the development, anatomy, and pathology ESC Working Group. *Cardiovasc Res*. 109: 204–216.

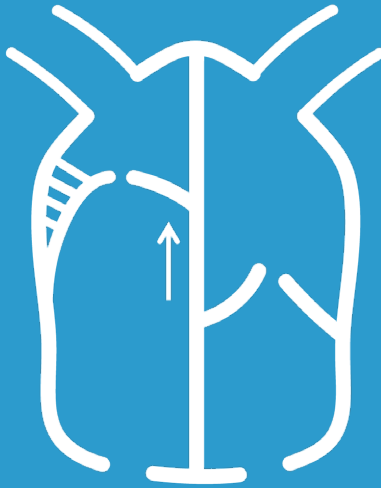
[PMID: 26811390](#)

Warnes, CA, Williams, RG, Bashore, TM, et al. 2008. ACC/AHA 2008 Guidelines for the Management of Adults with Congenital Heart Disease: a report of the American College of Cardiology/American Heart Association Task Force on Practice Guidelines (writing committee to develop guidelines on the management of adults with congenital heart disease). *Circulation*. 118: e714–e833.

[PMID: 18997169](#)

## Chapter 6

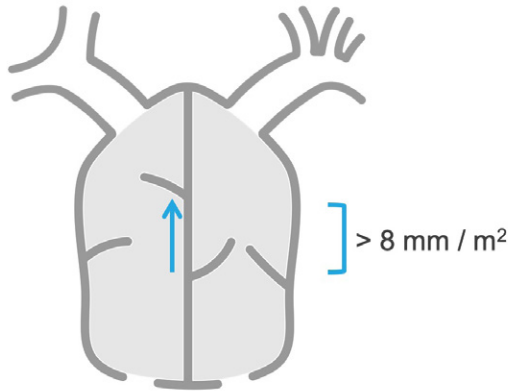
# EBSTEIN ANOMALY





# Ebstein anomaly

Ebstein anomaly is a congenitally abnormal position of the tricuspid valve involving the septal and sometimes the posterior leaflet. It results from the failure of the leaflets to delaminate from the septum.



The diagnostic criteria, using echocardiography, is apical displacement of the septal leaflet of the tricuspid valve by  $> 8 \text{ mm} / \text{m}^2$ . This measurement is best taken from the apical four-chamber view. The offset is usually most easily determined when the leaflets are in a closed position during diastole.

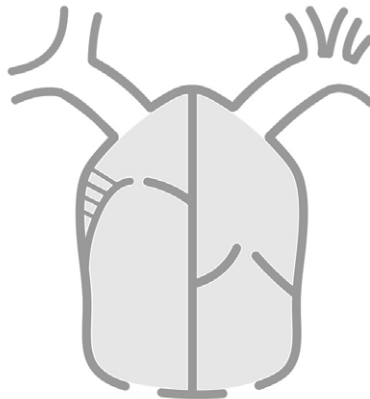
## ***The leaflets***

Failure of the leaflets to delaminate or separate cleanly from the septum occurs to a variable degree. It can result in the tricuspid valve orifice being displaced a little or a lot. In some cases the septal leaflet is absorbed into the septal myocardium itself.



The septal leaflet is always involved in Ebstein anomaly and the posterior or mural leaflet is sometimes involved. As they are pushed towards the apex and anteriorly towards the outflow tract, the anterior leaflet undergoes compensatory changes.

The anterior leaflet is often elongated and sail-like, with unusually thickened septal attachments directly into the free wall of the right ventricular myocardium.



The abnormal leaflets and their abnormal coaptation point often result in tricuspid regurgitation. However, the degree of displacement is not related to the degree of valve dysfunction.

## Further reading

Alonso-González, R, Dimopoulos, K, Oliver, JM, et al. 2010. The right heart and pulmonary circulation (IX). The right heart in adults with congenital heart disease. *Rev Esp Cardiol.* **63**: 1070–1086.

[PMID: 20804703](#)

Baumgartner, H, Bonhoeffer, P, De Groot, NM, et al. 2010. ESC Guidelines for the management of grown-up congenital heart disease (new version 2010). *European Heart Journal.* **23**: 2915–2957.

[PMID: 20801927](#)

Di Salvo, G, Miller, O, Babu Narayan, S, et al. 2018. Imaging the adult with congenital heart disease: a multimodality imaging approach–position paper from the EACVI. *Eur Heart J Cardiovasc Imaging.* **19**: 1077–1098.

[PMID: 30084968](#)

Eidem, BW, Cetta, F, and O'Leary PW. 2010. *Echocardiography in pediatric and adult congenital heart disease*. 2nd edition. Philadelphia: Lippincott Williams & Wilkins.

Gatzoulis, M, Webb, G, and Daubeney, P. 2011. *Diagnosis and management of adult congenital heart disease*. 3rd edition. Philadelphia: Saunders Elsevier.

Ho, SY, Rigby, ML, and Anderson, RH. 2005. *Echocardiography in congenital heart disease made simple*. 1st edition. London: Imperial College Press.

Lee, CM, Sheehan, FH, Bouzas, B, et al. 2013. The shape and function of the right ventricle in Ebstein's anomaly. *Int J Cardiol.* **167**: 704–710.

[PMID: 22465348](#)

Li, W, West, C, McGhie, J, et al. 2018. Consensus recommendations for echocardiography in adults with congenital heart defects from the International Society of Adult Congenital Heart Disease (ISACHD). *Int J Cardiol.* **272**: 77–83.

[PMID: 30017529](#)

Warnes, CA, Williams, RG, Bashore, TM, et al. 2008. ACC/AHA 2008 Guidelines for the Management of Adults with Congenital Heart Disease: a report of the American College of Cardiology/American Heart Association Task Force on Practice Guidelines (writing committee to develop guidelines on the management of adults with congenital heart disease). *Circulation*. **118**: e714–e833.

[PMID: 18997169](#)

## Chapter 7

# RIGHT VENTRICULAR OUTFLOW LESIONS



# Right ventricular outflow lesions

Obstruction to right ventricular outflow is a common lesion seen in congenital heart patients and can occur in isolation or in combination with other defects. It can occur anywhere along the course of outflow, from the ventricular cavity to the pulmonary artery branches.

## Right ventricular pressure

Increased pressure within the right ventricle is common to all types of right ventricular outflow obstruction. The following secondary signs of high right ventricular (RV) pressure are also useful to look for.

- Right ventricular hypertrophy
- Septal flattening



Careful assessment of right ventricle size and systolic function is required, as pressure overload will eventually cause right ventricle failure.

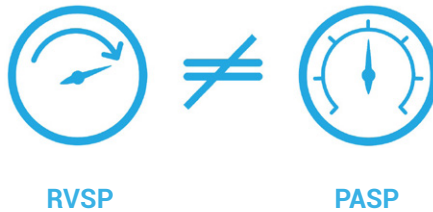
## Pulmonary artery pressure

An important consideration in evaluating right ventricular outflow lesions is the estimation of pulmonary artery systolic pressure (PASP). In adult echocardiography, a commonly used strategy to determine pulmonary artery systolic pressure is to use the peak velocity of the tricuspid regurgitation jet.

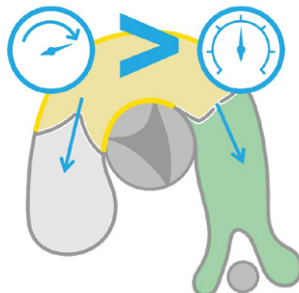
### $4VTR_{max}^2 + \text{right atrial pressure}$

This formula calculates the right ventricular systolic pressure (RVSP). It is commonly used as a surrogate for pulmonary artery systolic pressure but carries the assumption of no outflow obstruction.

### If RV outflow obstruction is present

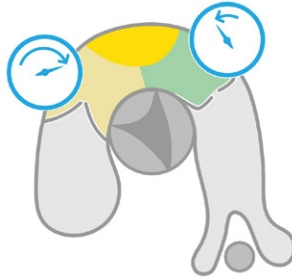


What remains true, is that the peak velocity of the tricuspid regurgitant (TR) jet still reflects right ventricular pressure but no longer reflects pulmonary arterial pressure. As there is an obstruction in right ventricular outflow, there will be a backup of pressure in the right ventricle. The right ventricular pressure must always be higher than the pulmonary arterial pressure, or in echo terms, the peak TR velocity should be higher than the peak outflow velocity.

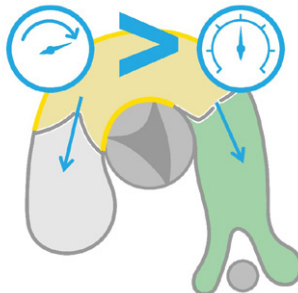


## Double-chambered right ventricle

Anomalous muscle bundles or anterior malposition of the moderator band can cause intracavitary obstruction, which creates a double-chambered right ventricle—a high-pressure proximal inlet chamber and a lower-pressure distal or outflow chamber. The anatomical location of the obstruction will affect the degree of right ventricular adaptation to the high pressures.



In these cases, the TR jet can be used to calculate the pressure of the proximal high-pressure chamber but bears no relation anymore to the pulmonary pressure. The proximal right ventricular systolic pressure can still be useful for serial assessment in cases where it is difficult to ascertain the degree of obstruction.





A double-chambered right ventricle is commonly associated with the presence of a ventricular septal defect, which usually drains into the high-pressure chamber.



*The pressure differential between the left and proximal right ventricles can be low (depending on the degree of obstruction) resulting in low-velocity, left-to-right flow, which can make these VSDs easy to miss with color Doppler, as the flow will be laminar.*



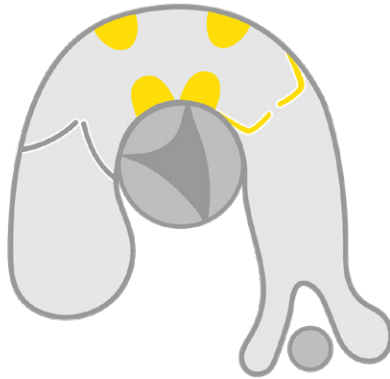*Careful inspection with 2D imaging is required in these cases.*

In cases of severe obstruction or if the obstruction worsens during exercise, the proximal chamber pressure may exceed systemic pressure and cause the VSD shunt direction to become right-to-left, causing desaturation on exercise and even cyanosis.



## Infundibular stenosis

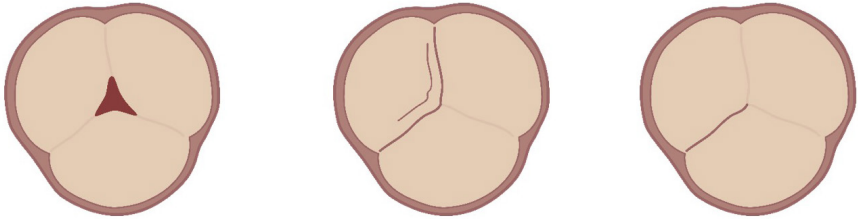
The infundibulum is the region of the right ventricular outflow tract just below the pulmonary valve. Abnormal thickening of the musculature can cause infundibular stenosis (also known as subvalvular stenosis). High-velocity jets through this region can impinge on the pulmonary valve, causing scarring and thickening or degeneration of the leaflets, subsequently affecting valve function.



Infundibular stenosis can also occur due to deviation of the outlet septum, as commonly seen in Tetralogy of Fallot. It is the most clinically important lesion in Tetralogy of Fallot, due to its ability to reverse shunting across the ventricular septal defect in cases of severe obstruction (causing cyanosis).

# Valvular stenosis

Stenosis at valve level is the most common type of outflow obstruction and is due to malformation of the valve leaflets.



On 2D imaging, the valve leaflets will typically dome in systole and the color flow Doppler will show turbulence beginning at the level of the leaflets.



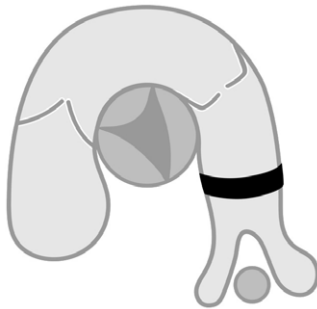
*Good parasternal windows are desirable, however, remember that apical and subcostal windows do provide alternative imaging strategies.*



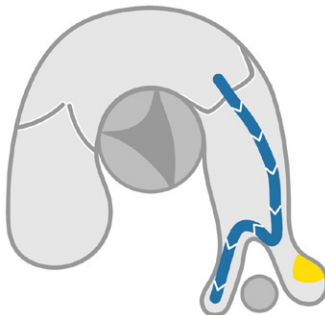
*Detecting valvular stenosis has important implications for management because it opens options to percutaneous solutions such as balloon valvuloplasty.*

## Pulmonary artery stenosis

Stenosis in the main pulmonary artery in adults is usually a discrete narrowing and can be the postoperative sequela of previous pulmonary artery banding or related to surgical anastomosis sites. Significant tubular hypoplasia of the main pulmonary artery can occur but is usually part of a wider pathology such as pulmonary atresia.



Stenosis can also occur in the major branches of the left and right pulmonary arteries. Branch stenosis is not always associated with a commensurate rise in right ventricular pressure. Stenosis in one branch can often induce compensatory increased flow to the other branch without the backup of pressure in the right ventricle seen in other types of right ventricular outflow obstruction.



## Further reading

Alonso-González, R, Dimopoulos, K, Oliver, JM, et al. 2010. The right heart and pulmonary circulation (IX). The right heart in adults with congenital heart disease. *Rev Esp Cardiol.* **63**: 1070–1086.

[PMID: 20804703](#)

Baumgartner, H, Bonhoeffer, P, De Groot, NM, et al. 2010. ESC Guidelines for the management of grown-up congenital heart disease (new version 2010). *European Heart Journal.* **23**: 2915–2957.

[PMID: 20801927](#)

Di Salvo, G, Miller, O, Babu Narayan, S, et al. 2018. Imaging the adult with congenital heart disease: a multimodality imaging approach–position paper from the EACVI. *Eur Heart J Cardiovasc Imaging.* **19**: 1077–1098.

[PMID: 30084968](#)

Eidem, BW, Cetta, F, and O'Leary PW. 2010. *Echocardiography in pediatric and adult congenital heart disease*. 2nd edition. Philadelphia: Lippincott Williams & Wilkins.

Gatzoulis, M, Webb, G, and Daubeney, P. 2011. *Diagnosis and management of adult congenital heart disease*. 3rd edition. Philadelphia: Saunders Elsevier.

Ho, SY, Rigby, ML, and Anderson, RH. 2005. *Echocardiography in congenital heart disease made simple*. 1st edition. London: Imperial College Press.

Li, W, West, C, McGhie, J, et al. 2018. Consensus recommendations for echocardiography in adults with congenital heart defects from the International Society of Adult Congenital Heart Disease (ISACHD). *Int J Cardiol.* **272**: 77–83.

[PMID: 30017529](#)

Loukas, M, Housman, B, Blaak, C, et al. 2013. Double-chambered right ventricle: a review. *Cardiovasc Pathol.* **22**: 417–423.

[PMID: 23701985](#)

Silvilairat, S, Cabalka, AK, Cetta, F, et al. 2005. Echocardiographic assessment of isolated pulmonary valve stenosis: which outpatient Doppler gradient has the most clinical validity? *J Am Soc of Echocardiogr*. **18**: 1137–1142.

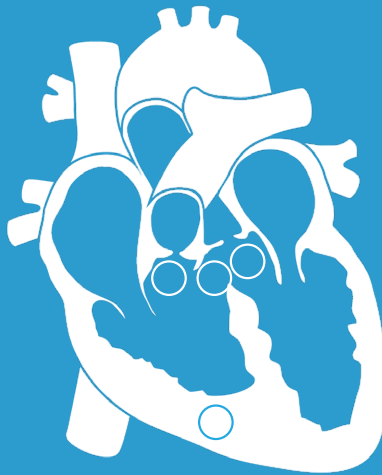[PMID: 16275521](#)

Warnes, CA, Williams, RG, Bashore, TM, et al. 2008. ACC/AHA 2008 Guidelines for the Management of Adults with Congenital Heart Disease: a report of the American College of Cardiology/American Heart Association Task Force on Practice Guidelines (writing committee to develop guidelines on the management of adults with congenital heart disease). *Circulation*. **118**: e714–e833.

[PMID: 18997169](#)

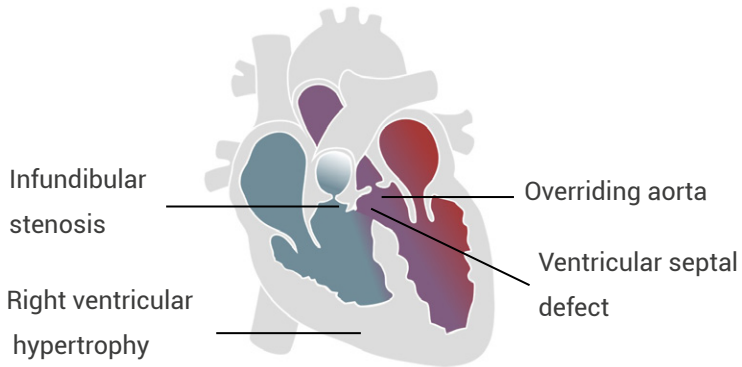
## Chapter 8

# TETRALOGY OF FALLOT



# Tetralogy of Fallot

Tetralogy of Fallot (ToF) is the most common form of cyanotic congenital heart disease and results from a single embryologic anomaly—deviation of the outlet septum. This one anomaly causes the four anatomic features first described by Étienne-Louis Arthur Fallot in 1888.



In practice, the level of stenosis has been seen to be at infundibular or also at valvular level and the VSD can involve a combination of outlet and perimembranous septae.



# Tetralogy of Fallot in babies

Fallot described the original condition, after witnessing many blue babies, describing the cyanotic nature of the disease. The degree of cyanosis is determined by the severity of outflow obstruction. Increasing outflow obstruction will cause a rise in right ventricular systolic pressure, which can supersede left ventricular pressure and reverse shunt flow to induce a right-to-left shunt. This may only occur during stress such as crying or feeding—so-called Tet spells—or in very severe cases, may occur at rest.



## Tet spells

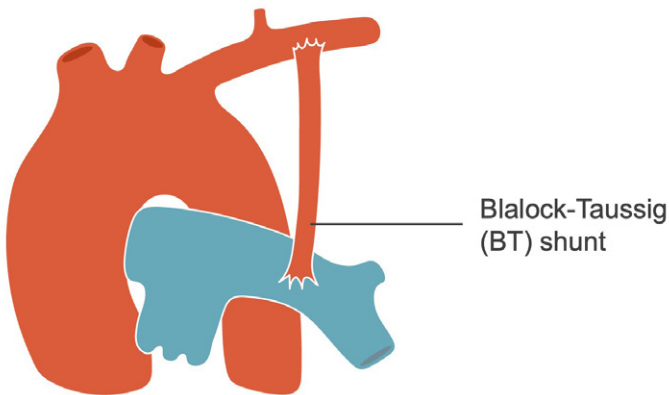
Tet spells are a transient reversal of VSD shunting, which result in a right-to-left shunt across the ventricular septal defect. This increases the level of deoxygenated blood in the systemic circulation. Sometimes toddlers will self-regulate by squatting or bringing their chest to their knees. This increases the systemic vascular resistance, reducing or even reversing the right-to-left shunt; therefore, reducing the cyanosis as well.



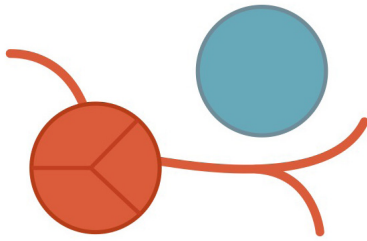
## Preoperative assessment

Important preoperative considerations include the size of the ventricular septal defect, the location of outflow obstruction (infundibular will require resection, valvular may require valvotomy), size of the branch pulmonary arteries, and any coronary artery anomalies.

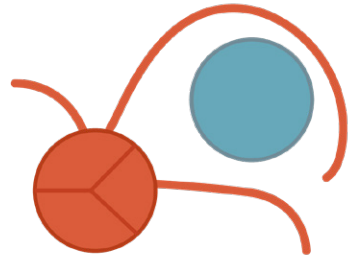
Undersized branch pulmonary arteries provide increased resistance to flow entering the pulmonary circulation. Flow can be promoted with the insertion of a Blalock-Taussig (BT) shunt, which not only increases flow to the pulmonary system but also encourages the branch arteries to grow, prior to total corrective surgery.



The most important coronary anomaly is an anomalous left anterior descending artery (LAD), which arises from the right coronary artery—this LAD then courses anteriorly in front of the right ventricular outflow tract or main pulmonary artery, providing an obstacle to the surgeon's approach.



Normal



Anomalous left anterior  
descending artery

This type of outflow obstruction can be resolved by inserting an extracardiac right ventricular to pulmonary artery conduit, to provide a second pathway for blood to reach the pulmonary system.

# Repair of Tetralogy of Fallot

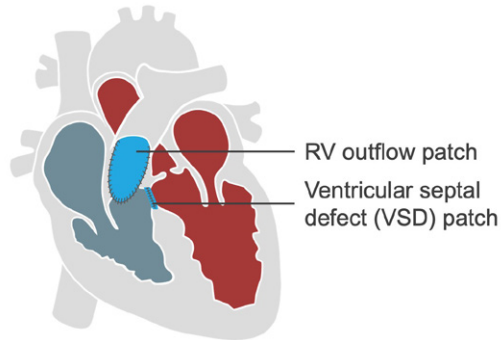
The surgery to relieve the outflow obstruction requires careful assessment. Knowledge of which surgical technique was performed is invaluable for continued patient follow-up.

If the patient has an anomalous coronary artery, an extracardiac conduit may be placed.


- Nonstandard echo views will be required to locate the extracardiac conduit, which would not be seen in the standard imaging planes, therefore, easy to miss.
- These conduits can become quite calcified and stenotic or the valve can become regurgitant or infected.



Older surgical techniques involved the use of a transannular patch (along with VSD patching), which interrupted the integrity of the pulmonary valve, causing pulmonary regurgitation, which progressed over time.



Currently, more percutaneous valve replacements are performed and knowledge of the anomalous coronary artery can also have significant implications for this procedure.

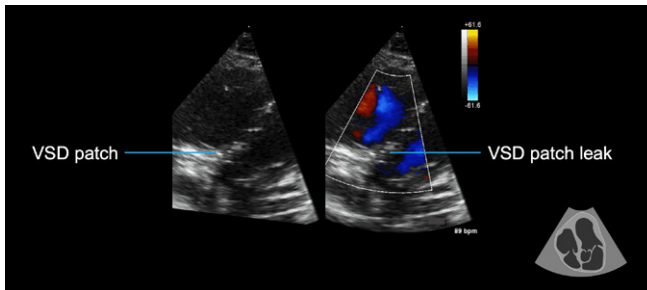


# Postoperative assessment in adults

Echocardiography in adult patients centers around focusing on the areas of the original lesion and the repair.

## Checking VSD and aorta for complications

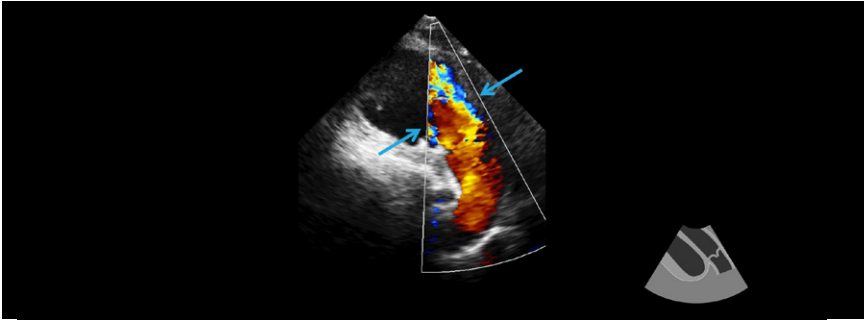
The ventricular septal defect patch should be checked to ensure it remains intact and free from any evidence of endocarditis or leaks. A large VSD patch can contribute to left ventricular dysfunction.



The formerly overriding aortic root is often dilated and in some cases, can cause significant aortic regurgitation.

## Pulmonary outflow assessment

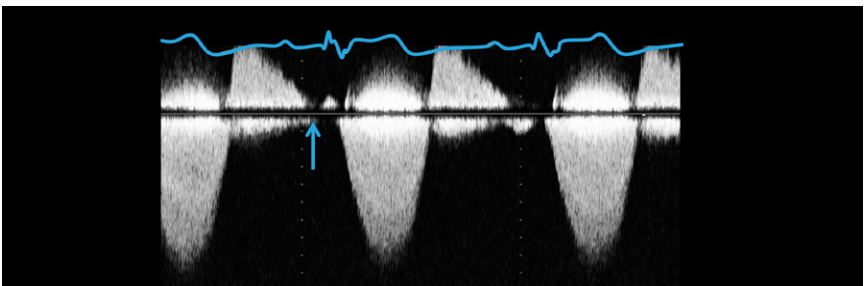
Pulmonary regurgitation causes increased volume loading of the right ventricle. As significant pulmonary regurgitation is fairly rare, outside of congenital heart disease, it is often poorly understood and easy to misdiagnose or classify incorrectly. Some of the basic principles (e.g., the width of the regurgitant jet at the valve or right ventricular outflow level) are the same as for aortic regurgitation.



However, there are significant differences owing to the different physiologic pressures in the right ventricle and pulmonary artery. As the right ventricle and pulmonary artery both operate at low pressure in diastole, equalization of pressures occurs more frequently. Remember, pressure differences are required to generate flow; when the pressures equalize, there is no flow. This is important and particularly relevant to pulmonary regurgitation because it means that even though the leak can be severe (i.e., occupy the entire right ventricular outflow tract width), there may not be any flow in late diastole.



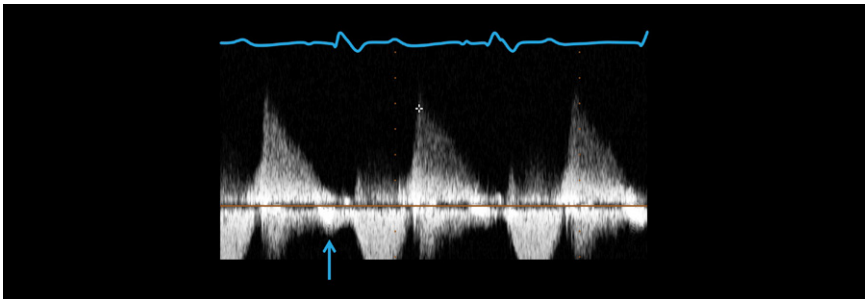
*Pulmonary regurgitation differs from aortic regurgitation, as it is not holodiastolic but rather is abbreviated and therefore easy to miss.*



## Evaluating diastolic function

The pulmonary Doppler signal demonstrates pressure differences. In the presence of significant pulmonary regurgitation, we assume that the equalization of pressure is due to the regurgitation. However, elevated right ventricular diastolic pressure can also be a result of significant diastolic dysfunction.

Diastolic function is the sum of the compliance of the ventricle plus the filling pressures. The pulmonary Doppler signal also gives useful information regarding diastolic function. A forward flow, prior to the onset of systole, is related to atrial contraction and is sometimes known as a forward a wave.

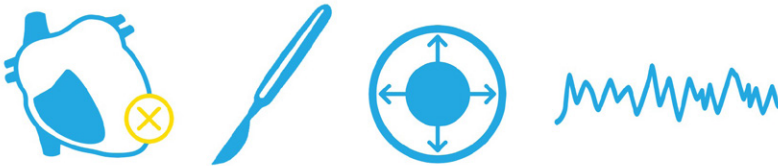


This reflects right ventricular pressure superseding pulmonary arterial pressure and causing a premature opening of the pulmonary valve. When this occurs consistently throughout the respiratory cycle, this is known as restrictive physiology.



## ***Right ventricular assessment***

The right ventricle is affected not only by the pulmonary regurgitation but also by fibrosis and scarring, both from the original condition (due to abnormal development of the myocytes) and from surgical incisions and infundibular patches. This can be a substrate for arrhythmia and sudden death.



Assessment of right ventricular size and function form an important element of follow-up echocardiography in these patients; however, dysfunction of the outflow tract may not be included in traditional measures and 3D assessment is recommended. Where available, cardiac magnetic resonance imaging is recommended.

## Further reading

Alonso-González, R, Dimopoulos, K, Oliver, JM, et al. 2010. The right heart and pulmonary circulation (IX). The right heart in adults with congenital heart disease. *Rev Esp Cardiol.* **63**: 1070–1086.

[PMID: 20804703](#)

Baumgartner, H, Bonhoeffer, P, De Groot, NM, et al. 2010. ESC Guidelines for the management of grown-up congenital heart disease (new version 2010). *European Heart Journal.* **23**: 2915–2957.

[PMID: 20801927](#)

Di Salvo, G, Miller, O, Babu Narayan, S, et al. 2018. Imaging the adult with congenital heart disease: a multimodality imaging approach–position paper from the EACVI. *Eur Heart J Cardiovasc Imaging.* **19**: 1077–1098.

[PMID: 30084968](#)

Eidem, BW, Cetta, F, and O'Leary PW. 2010. *Echocardiography in pediatric and adult congenital heart disease*. 2nd edition. Philadelphia: Lippincott Williams & Wilkins.

Gatzoulis, M, Webb, G, and Daubeney, P. 2011. *Diagnosis and management of adult congenital heart disease*. 3rd edition. Philadelphia: Saunders Elsevier.

Ho, SY, Rigby, ML, and Anderson, RH. 2005. *Echocardiography in congenital heart disease made simple*. 1st edition. London: Imperial College Press.

Li, W, West, C, McGhie, J, et al. 2018. Consensus recommendations for echocardiography in adults with congenital heart defects from the International Society of Adult Congenital Heart Disease (ISACHD). *Int J Cardiol.* **272**: 77–83.

[PMID: 30017529](#)

Valente, AM, Cook, S, Festa, P, et al. 2014. Multimodality imaging guidelines for patients with repaired Tetralogy of Fallot: a report from the American Society of Echocardiography: developed in collaboration with the Society for Cardiovascular Magnetic Resonance and the Society for Pediatric Radiology. *J Am Soc Echocardiogr.* **27**: 111–141.


[PMID: 24468055](#)

Warnes, CA, Williams, RG, Bashore, TM, et al. 2008. ACC/AHA 2008 Guidelines for the Management of Adults with Congenital Heart Disease: a report of the American College of Cardiology/American Heart Association Task Force on Practice Guidelines (writing committee to develop guidelines on the management of adults with congenital heart disease). *Circulation.* **118**: e714–e833.

[PMID: 18997169](#)

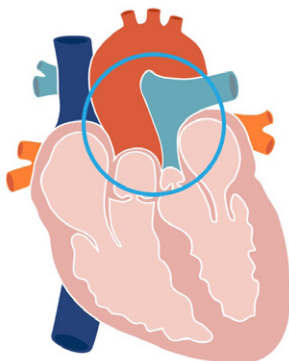
## Chapter 9

# TRANSPOSITION OF THE GREAT ARTERIES



## Transposition of the great arteries

Transposition of the great arteries (TGA) refers to, as the name suggests, a transposition or switching of the position of the great arteries, so they arise from the incorrect ventricle. In congenital terms, this is ventriculoarterial discordance. In this condition, the abnormal spiralling of the conotruncus results in the great arteries lying in parallel to each other, instead of assuming their usual crossover relationship.



The term transposition is used when there is a direct exchange of arterial position, however, in many other cases the term malposition might be more appropriate. This is especially so when combined with other forms of congenital heart disease (e.g., double outlet right ventricle hearts—the aorta may lie anterior to the pulmonary artery but as both arteries come from the right ventricle, there is not a direct exchange, as the left ventricle has no great artery).

One of the fundamental issues with TGA is that the right ventricle connects to the aorta, and therefore, supplies the systemic circulation at a very high pressure. This is not sustainable long-term and invariably leads to heart failure.



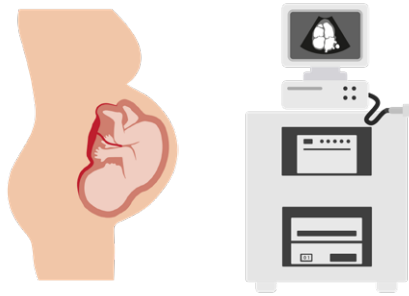
Ventricular looping has a major impact on the clinical outcome. When the ventricles loop normally to the right and so remain in their usual position, the effect of TGA is devastating, as two separate circulations are present and the systemic blood has no means of reoxygenation.



This condition, known as simple transposition, is not compatible with life, it is dependent on neonatal shunts such as the foramen ovale, ductus arteriosus remaining patent, and requires surgery within the first days of life. Ventricular looping to the left creates congenitally corrected transposition of the great arteries and maintains a normal circulation but with transposed ventricles and great arteries.

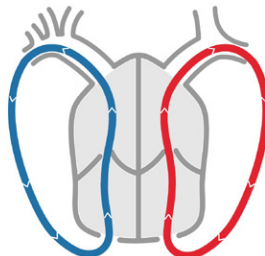
# Simple transposition

Simple transposition of the great arteries has a number of synonyms—d-TGA, dextro-transposition or simply just TGA. The dextro prefix refers to the normal pattern of ventricular looping to the right, which differentiates it from levo-transposition or ccTGA. This diagnosis can be made on fetal echo scans, which allows birthing and neonatal treatment plans to be organized as well as time for education of the expectant parents.

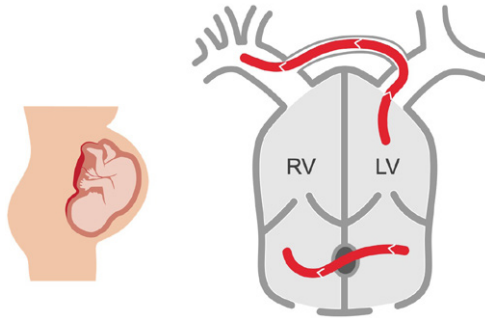


Transposed or malposed great arteries can co-exist with septal defects, coronary anomalies or many other complex congenital defects, which have a significant impact on treatment strategies.

The circulation of isolated simple transposition appears as two loops.



The circulation is not viable with two separate circulations and mixing only occurring while the foramen ovale and ductus arteriosus remain patent.



In the neonatal period, intervention is often required to ensure patency of these structures. Prostaglandin E1 is administered to maintain ductal patency and percutaneous balloon atrial septostomy can be performed to create an atrial level shunt (which will be patched closed later).



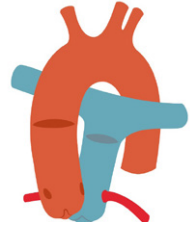
These interventions allow the babies to stabilize before proceeding to surgery, usually within the first two weeks of life.



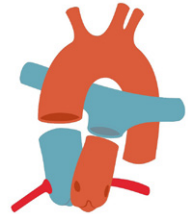
# Arterial Switch Operation

The arterial switch operation (also known as the Jatene procedure) is the current preferred surgical approach for simple TGA and is performed within the first two weeks of life. The surgery involves multiple maneuvers.

1. The great arteries are transected just above the sinotubular junction level.

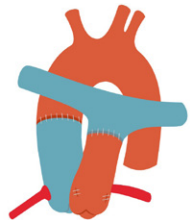


2. The coronary arteries are explanted with buttons from the aortic root and reimplanted into the neo-aortic root (formerly the pulmonary root).



3. The aorta is attached to the neo-aortic root.

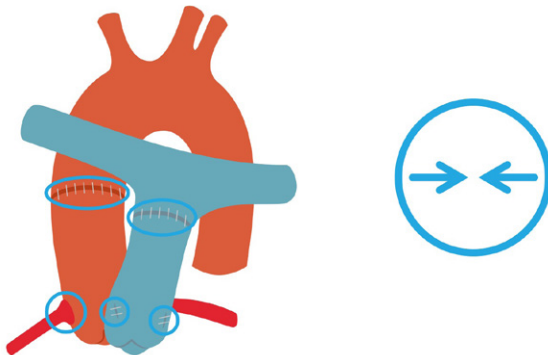
4. The pulmonary artery is repositioned anteriorly and connected to the neo-pulmonary root (formerly the aortic root). This step may involve the LeCompte maneuver, which wraps the branch pulmonary arteries on either side of the aorta.



## Common complications

The most common complications following the procedure usually relate directly to the procedure itself.

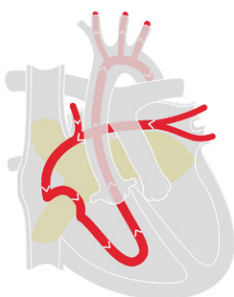
- Left ventricular dysfunction secondary to myocardial ischemia or infarction associated with relocation of the coronary arteries.
- Shrinkage or scarring of the coronary buttons or kinking of the arteries.
- Supravalvular stenosis caused by scarring at any of the anastomosis sites—in either the aorta or pulmonary artery.
- Dilatation of the neo-aortic root. This tissue is former pulmonary tissue now exposed to systemic pressure and dilatation can cause aortic valve regurgitation.
- Pulmonary branch stenosis, due to stretching of the branch arteries or dilatation of the aortic root.



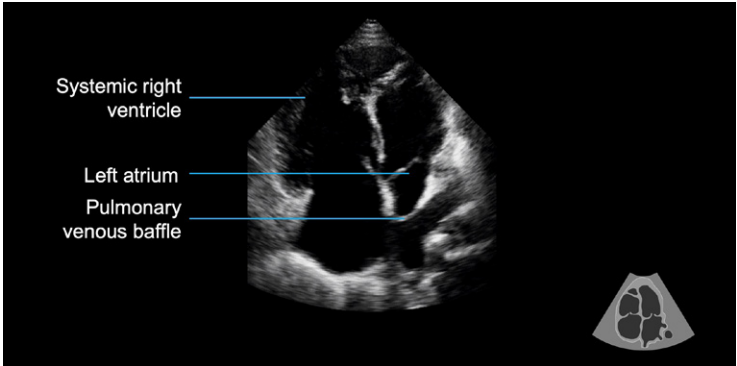
## Atrial switch operation

The atrial switch operation was the procedure of choice for simple transposition in the 1970s and 1980s. Complications were common, notably right ventricular failure induced by supporting the systemic circulation. It is no longer performed for simple transposition, however, patients from this era are now in their 30s and 40s and require careful follow up, including echocardiography assessment.

The atrial switch operation redirects blood flow at atrial level, to facilitate mixing of the circulations.



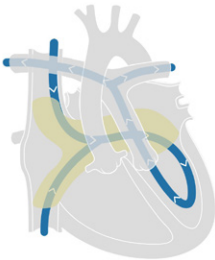
Baffles are used to redirect pulmonary venous blood flow into the right atrium and out to the systemic circulation—allowing oxygen-rich blood to reach the body. While the circulation is corrected, the right ventricle is forced to support a high-pressure systemic circulation, which invariably will fail. The right ventricle has a high afterload, and so the usual echo appearance of a systemic right ventricle is hypertrophied, dilated, and commonly has reduced systolic function. In addition, the tricuspid valve annulus can dilate and result in functional regurgitation, adding volume loading to the already pressure-loaded ventricle. These factors create a substrate for right-heart failure.



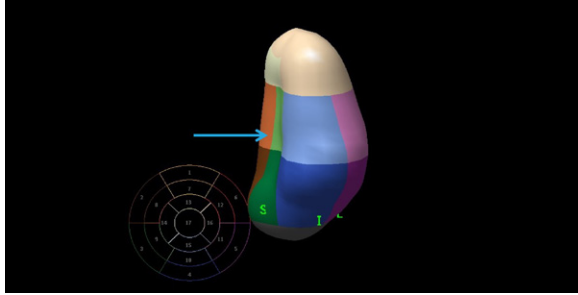
Thorough echo assessment of the right ventricle will include a fractional area change, TAPSE, S', and where possible, a 3D ejection fraction.



*These parameters are useful for serial assessment of the patient but standard reference ranges should not be used, as they are not valid for these loading conditions. The patient becomes their own control and clinical management may be guided by a change from the previous assessment.*



Venous return via the inferior and superior vena cava are redirected through a baffle to the left atrium, left ventricle, and pulmonary artery and blood travels to the lungs for reoxygenation. The sub-pulmonary left ventricle is compressed by an abnormal curvature of the ventricular septum, due to the higher-pressure systemic right ventricle.



The echo appearance of the sub-pulmonary left ventricle is usually a small cavity, which appears compressed in the parasternal views and apical four-chamber view but appears normal size in the apical two-chamber view, as it expands in an anterior and inferior plane. Systolic function is usually normal or hyperdynamic.

A normal sized pulmonary left ventricle (i.e., not compressed), suggests pressure or volume loading.



Volume loading can be a result of either valvular regurgitation (easily excluded with color Doppler) or a leak in the baffles. Small baffle leaks are common but larger leaks operate like a septal defect and can cause cyanosis. Intervention may be required and can be performed either percutaneously (with septal occluder plugs) or surgically.



Pressure loading can be the result of pulmonary valve stenosis or pulmonary hypertension. Pulmonary hypertension develops in about 10% of atrial switch patients. It is best detected by estimating the mean pulmonary artery pressure, using the Doppler from the pulmonary regurgitation signal.

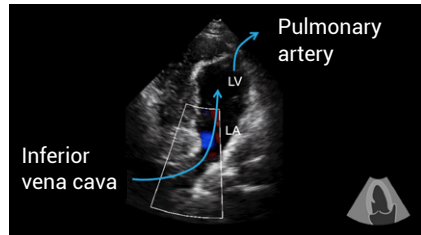
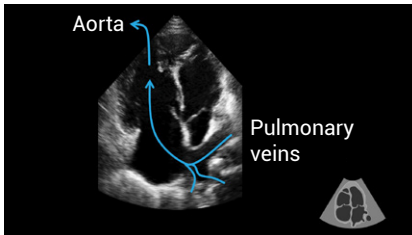
**Mean pulmonary artery pressure =  $4VPR$  early  $V_{max}^2$  + right atrial pressure**

The bileaflet mitral valve usually functions normally but where regurgitation exists its peak velocity will reflect pulmonary pressure, as does the tricuspid regurgitation in a structurally normal heart.

**Pulmonary artery systolic pressure (PASP) =  $4V-MR^2$  + central venous pressure**

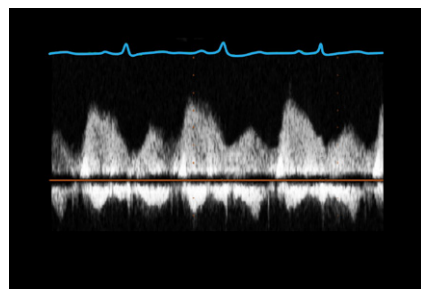
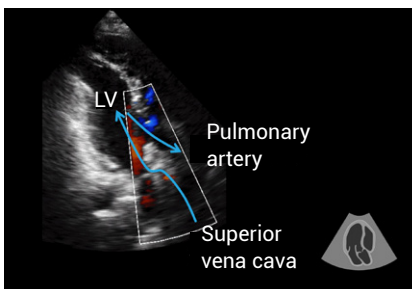
## **Baffle assessment**

Echocardiography is a useful tool to assess the atrial baffles, as they can usually be seen on transthoracic echo. The recommended views are below.



More information on this can be found in the recommended reading (Reference: Li et al., 2018)

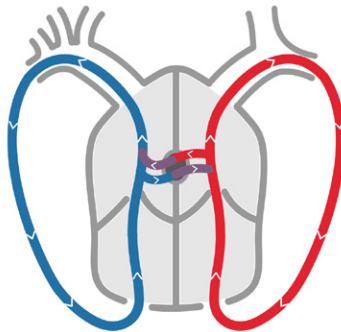
A pulsatile Doppler contour, always returning to the baseline, is more desirable than a low peak velocity, which should be below 1.5 m / sec. As baffle narrowing or stenosis progresses, the Doppler profile will become continuous. Increases in velocity can be related to cardiac output.



Pacing wires are sometimes noted in the superior vena cava to left atrial baffle and in the case of multiple wires, can be a source of obstruction.

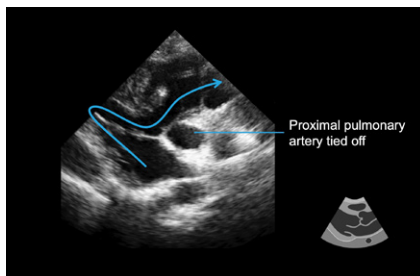
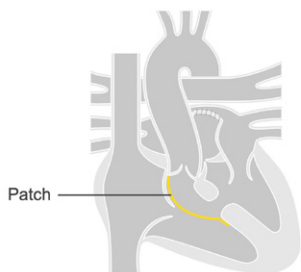
## Rastelli operation

The Rastelli procedure is still performed today in patients who have simple transposition with a sizeable ventricular septal defect and can also be performed in patients with similar anatomy (e.g., double outlet right ventricle). The ventricular septal defect provides a means for the two separate circulations to mix, and while oxygen saturations will be lower than normal and may cause cyanosis, they can still support life. For this reason, surgery can be delayed beyond the first few weeks of life, depending on the clinical progress of the baby. The major benefit of this surgery is that the left ventricle supports the systemic circulation.



The ventricular septal defect is incorporated into the circulation and used to redirect flow from the left ventricle to the aorta, which is located (abnormally) anteriorly. A patch is used to redirect the flow and the ventricular septal defect forms part of the left ventricular outflow—flow should remain laminar across the VSD, as any turbulence would increase the afterload on the left ventricle. The proximal pulmonary artery, which arises from the left ventricle, is tied off close to the root to keep the two circulations separated.



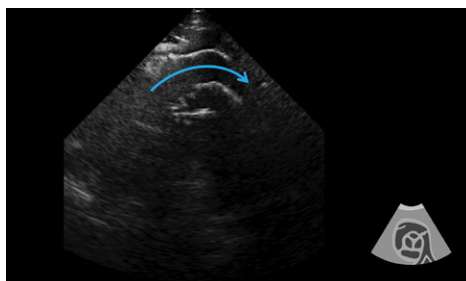


Echo assessment should ensure that left ventricular outflow is laminar ( $< 3.0$  m / sec) and the VSD patch is intact. Right ventricular outflow is provided by an extracardiac conduit to the distal pulmonary artery.



*The extracardiac position of the conduit requires the use of nonstandard echo windows to assess the conduit—usually very high parasternal windows with no other cardiac structures visible.*

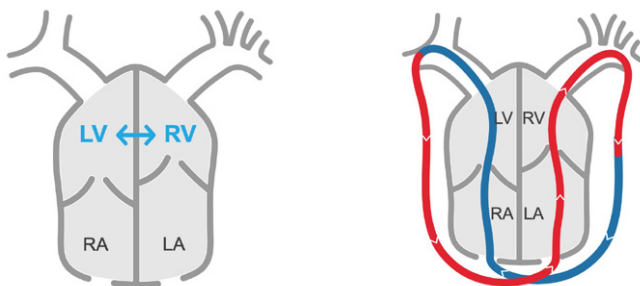
The conduits are often long and require Doppler assessment at both right ventricle and pulmonary artery ends to check for stenosis. Conduits are inserted in babies and over time the patients can outgrow the conduits or the valve in the conduit can degenerate. Echo is useful to check for regurgitation, stenosis, calcification or infective endocarditis.



## Congenitally corrected transposition of the great arteries

Congenitally corrected transposition of the great arteries (ccTGA) has a number of synonyms—levo-transposition, L-TGA, ventricular inversion. It is commonly associated with ventricular septal defects, tricuspid valve abnormalities, valvular or subvalvular pulmonary stenosis, and abnormalities of heart position such as dextrocardia or mesocardia. Unusual position of the AV node can induce heart block.

It is termed congenitally corrected because despite the unusual position of the great arteries, the circulation is normal. The problem, however, is that the abnormal heart looping to the left means that the right ventricle supports the systemic circulation.



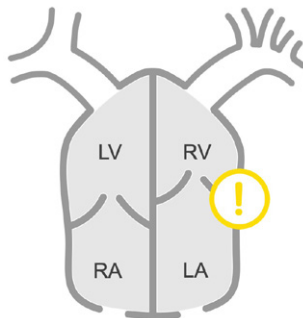
Key echo features of diagnosing ccTGA include identifying the morphological features of the right ventricle.

- Reversed cardiac crux is the key indicator—the left AV valve will be apically displaced.
- Identify the moderator band.
- The tricuspid valve has chordae, which directly attach to the septum, whereas mitral valve chordae insert into the papillary muscles.

### Other appearances

- A more side-by-side relationship between the left and right ventricles can be seen in the parasternal short-axis view, rather than the usual anterior-posterior relationship.
- A lack of aortomitral continuity. The tricuspid valve is not contiguous with the aortic valve.
- Dilatation, hypertrophy, and increased trabeculations are seen in the systemic right ventricle (easily confused for non-compaction of the left ventricle if the reversed cardiac crux is not appreciated). Reversed septal curvature is noted.

Dilatation of the systemic right ventricle, as a result of pressure loading, can lead to dilatation of the tricuspid annulus and result in significant functional regurgitation. Functional tricuspid regurgitation exacerbates right ventricular failure and little to no benefit is received from tricuspid valve surgery in these cases.



Tricuspid valve abnormalities can occur as an apical displacement of the valve leaflets, similar to Ebstein anomaly but without the anterior rotation of the annulus.



*These are referred to as Ebstein-like valves, which represent a structural abnormality and the right ventricle does benefit from surgery. The mechanism of tricuspid regurgitation in these patients needs to be carefully evaluated.*

Valvular or subvalvular pulmonary stenosis is an associated defect. The stenosis pressure-loads the left ventricle, which has the myocardial architecture to cope well with high pressure. The effect of significant stenosis can lead to dilatation of the usually compressed left ventricle. It can reverse the abnormal curvature of the septum, which reduces the size of the systemic right ventricle and is usually regarded as beneficial, provided adequate flow to the lungs is maintained.



Treatment for congenitally corrected TGA usually revolves around heart failure management but in some severe cases a procedure called the double switch is performed, which combines the atrial switch and arterial switch procedures.

## Further reading

Alonso-González, R, Dimopoulos, K, Oliver, JM, et al. 2010. The right heart and pulmonary circulation (IX). The right heart in adults with congenital heart disease. *Rev Esp Cardiol*. **63**: 1070–1086.

[PMID: 20804703](#)

Baumgartner, H, Bonhoeffer, P, De Groot, NM, et al. 2010. ESC Guidelines for the management of grown-up congenital heart disease (new version 2010). *European Heart Journal*. **23**: 2915–2957.

[PMID: 20801927](#)

Cohen, MS, Eidem, BW, Cetta, F, et al. 2016. Multimodality Imaging Guidelines of Patients with Transposition of the Great Arteries: A Report from the American Society of Echocardiography Developed in Collaboration with the Society for Cardiovascular Magnetic Resonance and the Society of Cardiovascular Computed Tomography. *J Am Soc Echocardiogr*. **29**: 571–621.

[PMID: 27372954](#)

Di Salvo, G, Miller, O, Babu Narayan, S, et al. 2018. Imaging the adult with congenital heart disease: a multimodality imaging approach–position paper from the EACVI. *Eur Heart J Cardiovasc Imaging*. **19**: 1077–1098.

[PMID: 30084968](#)

Eidem, BW, Cetta, F, and O'Leary PW. 2010. *Echocardiography in pediatric and adult congenital heart disease*. 2nd edition. Philadelphia: Lippincott Williams & Wilkins.

Gatzoulis, M, Webb, G, and Daubeney, P. 2011. *Diagnosis and management of adult congenital heart disease*. 3rd edition. Philadelphia: Saunders Elsevier.

Ho, SY, Rigby, ML, and Anderson, RH. 2005. *Echocardiography in congenital heart disease made simple*. 1st edition. London: Imperial College Press.

Li, W, West, C, McGhie, J, et al. 2018. Consensus recommendations for echocardiography in adults with congenital heart defects from the International Society of Adult Congenital Heart Disease (ISACHD). *Int J Cardiol.* **272**: 77–83.

[PMID: 30017529](#)

Warnes, CA, Williams, RG, Bashore, TM, et al. 2008. ACC/AHA 2008 Guidelines for the Management of Adults with Congenital Heart Disease: a report of the American College of Cardiology/American Heart Association Task Force on Practice Guidelines (writing committee to develop guidelines on the management of adults with congenital heart disease). *Circulation.* **118**: e714–e833.

[PMID: 18997169](#)



Become an expert by learning the most important clinical skills at [www.medmastery.com](http://www.medmastery.com).